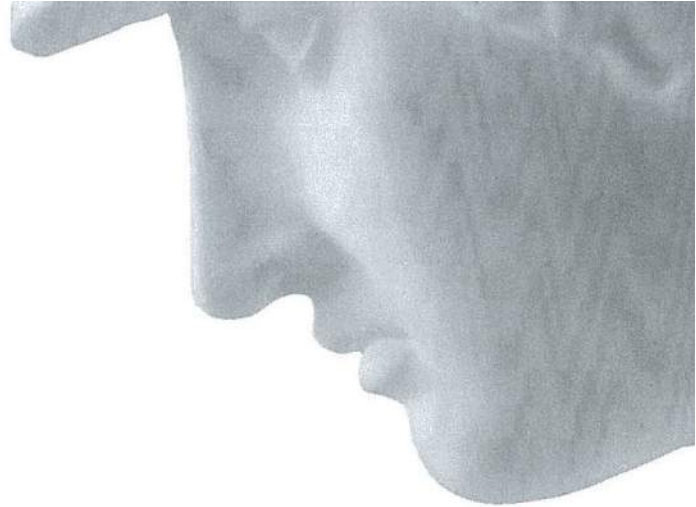




CURRENT THERAPY in Plastic Surgery

Joseph G. McCarthy
Robert D. Galiano
Sean G. Boutros





The Nasal Airway

STEVEN ROSS MOBLEY

RICHARD R. ORLANDI

DEAN M TORIUMI

The nasal airway is a complex, dynamic anatomic structure. In addition to septal deviation and turbinate hypertrophy, structural integrity of the internal and external nasal valves is a key element of airway patency. Detailed preoperative assessment of these four anatomic areas is critical for successful correction of nasal obstruction.

Etiopathogenesis

Nasal airway obstruction can involve an interplay between several reversible and nonreversible components. Reversible factors are related to the normal nasal cycle or to mucosal edema secondary to allergic or vasomotor rhinitis. Nonreversible anatomic components include a deviated septum, enlarged bony turbinate, nasal polyps, and weakened nasal valves.

The cause of the perceived symptom of nasal obstruction is occasionally related to a patient's poor understanding of the normal nasal cycle. Patients believe that any restriction to airflow from either nasal passage is a symptom of nasal airway obstruction. Educating patients about alternation in the laterality of nasal airflow is important and can be even more important after surgery. Patients with long-standing nasal obstruction may also be unfamiliar with the sensation of restored nasal airflow after successful surgery.

Classic reductive rhinoplasty that emphasizes removal or reduction of nasal tissue (or both) is a common cause of iatrogenic nasal airway compromise because the support of the nose is weakened. Reductive maneuvers can destabilize the nasal valve and lead to significant nasal valve compromise.

Nasal obstruction was previously considered synonymous with either septal deviation or turbinate

hypertrophy. As understanding of nasal function has become more sophisticated, it is now known that these conditions are not the only cause of obstruction. The stability and strength of the lateral nasal wall and external nasal valve can also greatly affect a patient's ability to breathe through the nose. In some patients the patency and integrity of the internal valve may be the most important aspect of the nasal airway. Conversely, a deviated septum may in fact have much less effect on airway patency than previously thought. Moreover, approximately 18% of nasal septa in the general population are "deviated."

In some patients, the external valve has also been shown to be an isolated cause of nasal obstruction, as documented by rhinomanometric studies. In these patients, improvement of external valve function corrects obstructive symptoms.

Pathologic Anatomy

The overall patency of the nasal valve is affected by the septum, turbinates, and internal and external nasal valves. The *internal valve* is defined as the area formed by the junction of the caudal edge of the upper lateral cartilage and the quadrangular cartilage and is bounded inferiorly by the floor of the nose and inferolaterally by the inferior turbinate. The *external valve* is defined as the entrance to the nares and consists of the alar sidewalls and crural cartilage. The size and patency of the nasal airway is dependent on both *static structures* and *dynamic forces*. *Static structures* relate to the position of the septum and the size of the inferior and middle turbinates. *Dynamic elements* include mucosal hypertrophy secondary to allergic or inflammatory rhinitis and the integrity of the internal and external nasal valves. Any congenital or acquired weakness of the upper or lower cartilage or their

investing soft tissue may affect the ability to maintain adequate nasal airflow volume. Understanding the concept of static structures and dynamic forces provides a critical foundation for successful treatment of nasal airway obstruction.

The internal nasal valve is the narrowest cross-sectional passage in the nose. The attachment of the caudal edge of the upper lateral cartilage to the septum forms an angle of approximately 10 to 15 degrees with a resulting cross-sectional area of 55 to 83 mm. During normal respiration, one of the physiologic roles of the nasal valve is to create some element of airflow turbulence. When air is inspired, it is forced to pass through the narrow nasal valve area, which increases its speed and pressure. As the speed increases, laminar flow is disrupted and increasing turbulence results. Some turbulence is necessary for normal nasal function. Turbulence serves to promote contact between air and mucosa and allows the inspired air to be cleansed of particles, humidified, and heated or cooled. When the nasal valve is compromised, exaggerated turbulence occurs and leads to collapse at lower pressure, thereby contributing to the symptom of nasal obstruction.

Diagnostic Studies

Diagnosis of nasal valve obstruction relies heavily on careful consultation. History taking should focus on the laterality of symptoms, association with allergies, patterns of congestion (daytime, nighttime, seasonal, etc.), previous nasal surgery or nasal trauma, and response to medications.

Patients may provide a history of improved nasal breathing after the application of external nasal splints (e.g., Breathe Right). This information can provide partial evidence of internal or external valve collapse because these devices add support to the lateral nasal wall.

The physical examination begins by observation of the patient's breathing. An inexperienced examiner may mistakenly proceed directly to topical decongestion followed by anterior rhinoscopy with a nasal speculum and lose the ability to diagnose airway abnormalities best appreciated by direct observation of the patient's nasal breathing. Observation may also demonstrate valvular dysfunction, which exceeds septal deviation as the primary cause of nasal airflow obstruction. Close inspection of the nose may reveal medial collapse or "pinching" in the supraalar region. Close observation of the supraalar fold (corresponding to the internal nasal valve) often reveals dynamic collapse with exertional nasal breathing. Forceful nasal breathing can serve to identify areas of inherent weakness in the patient's nasal valve. Collapse in the area of the supraalar crease may be observed, and even collapse of the alar rim can be seen. After observing normal nasal

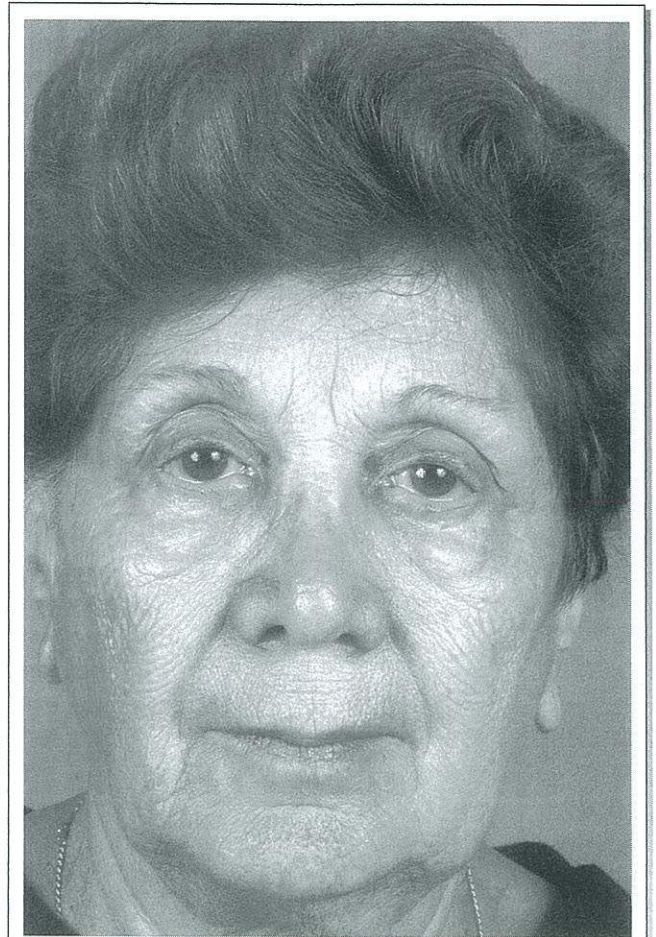

Figure 1 • The classic "inverted V" deformity caused by aggressive dorsal resection and middle vault collapse.

respiration and exertional nasal respiration, the patient is instructed to cover one nostril at a time. This maneuver documents which side is predominately contributing to the patient's symptom of nasal obstruction.

After cosmetic rhinoplasty with overresection of the dorsum and collapse of the middle vault, patients can have an "inverted V" deformity (Fig. 1). This physical sign is strong evidence of internal valve collapse and often indicates patients who will benefit from placement of a spreader graft.

After observation, the intranasal examination should be performed with a light source, nasal speculum, and fine probe. A topical decongestant and anesthetic agent should also be available. The physiologic and structural interrelationships of the intranasal anatomy, especially the four most common culprits of nasal airway obstruction (the septum, turbinates, internal valves, and external valves), are individually examined. An assessment of turbinate size should be made before the application of any decongestant. Routine decongestion of all patients should be performed to avoid missing



Figure 2 • The Cottle maneuver.

pathology such as synechiae or other posterior abnormalities obscured by the turbinates. Either rigid or flexible nasal endoscopy should be performed when necessary to evaluate the more posterior parts of the nasal cavity that can be obscured by significant septal deviation.

Lateralization of the cheek and lateral wall of the nose (the Cottle maneuver) may result in improved nasal airflow and is helpful in distinguishing patients with valvular dysfunction from those with septal or turbinate pathology (Fig. 2).

After the diagnosis of nasal valve collapse has been established, a more accurate determination of the contribution from either the internal or external nasal valves can be obtained by intranasal palpation with a fine probe. During quiet and forced inspiration, lateral displacement of the internal and external valves can produce dramatic improvements in breathing on the affected side and assist in making an accurate diagnosis.

Other techniques such as acoustic rhinometry and rhinomanometry are used occasionally to help diagnose obstruction of the nasal airway. Both have drawbacks and limitations that preclude their routine use.

An evolving problem in the treatment of nasal obstruction is the justification of nasal airway operations to third-party insurance carriers. It is not uncommon for insurance companies to require a preoperative computed tomographic (CT) scan to document septal irregularities. This practice should be discouraged because it adds unnecessary cost to medical care and exposes the patient to a needless dose of radiation. Moreover, the static images generated by CT scanning provide little information about more dynamic problems such as a weak lateral nasal wall or nasal valve collapse.

Intranasal photography is technically difficult, requires costly equipment, and is impractical as a means of photodocumentation.

Goals of Reconstruction

The primary goal of any nasal operation should be to improve the patient's breathing, even in cases undertaken for both functional and aesthetic reasons. The surgeon should accurately diagnose the causative pathology preoperatively and perform the surgery by using a problem-oriented approach.

Treatment

Septoplasty is an often underappreciated operation given its potential complexity. Most septoplasty operations can be successfully performed via an endonasal approach. However, consideration should be given to an external approach for revision septoplasty, correction of severe caudal and high superior deflection, and insertion of spreader grafts.

It is the surgeon's obligation to qualify an operation as a true septoplasty only in patients in whom the operation is performed to improve all deviated parts of the septum (cartilaginous and bony). Incomplete attention to the entire cartilaginous and bony septum is not only surgically inadequate to improve the airway but may also make secondary septal surgery more difficult. Revision septoplasty to correct posterior deflection not addressed in the primary operation is inherently more difficult than primary septoplasty. Dissection between the bilaterally apposed mucoperichondrial flaps can be technically demanding and can place the patient at an increased risk for septal perforation.

If fixed anatomic obstruction is corrected by septoplasty without dynamic forms of nasal obstruction (i.e., valve collapse) being corrected, the patient may experience persistent obstruction. Spreader grafts are particularly useful for correction of internal nasal valve collapse, as demonstrated in patients with an overly narrow middle nasal vault (often seen as an "inverted V deformity" on frontal view). Spreader grafts measure approximately 5 to 15 mm

in length, 3 to 5 mm in width, and 1 to 2 mm in thickness. They are typically positioned from the osseocartilaginous junction to a point just cephalad to the septal angle. In the endonasal approach, precise submucosal tunnels must be developed that are sufficiently tight to prevent shifting of the graft. With an external or "open" approach, the grafts can be directly inserted between the upper lateral cartilage and septal cartilage and sutured in place (Fig. 3). The spreader grafts ensure that adequate middle vault width is established and inferomedial collapse of the internal valve is prevented.

Alar batten grafts are curvilinear cartilage grafts that are placed in a precise pocket at the point of maximal lateral wall collapse or supraalar pinching. The grafts may be fashioned from curved pieces of septal cartilage or from the cavum or cymba concha of the ear. Batten grafts are normally placed in a precise pocket lateral to the lateral crura at the point of maximal lateral wall collapse. This area can be easily identified as a prominent area of lateral wall medialization or pinching (Fig. 4). This is also

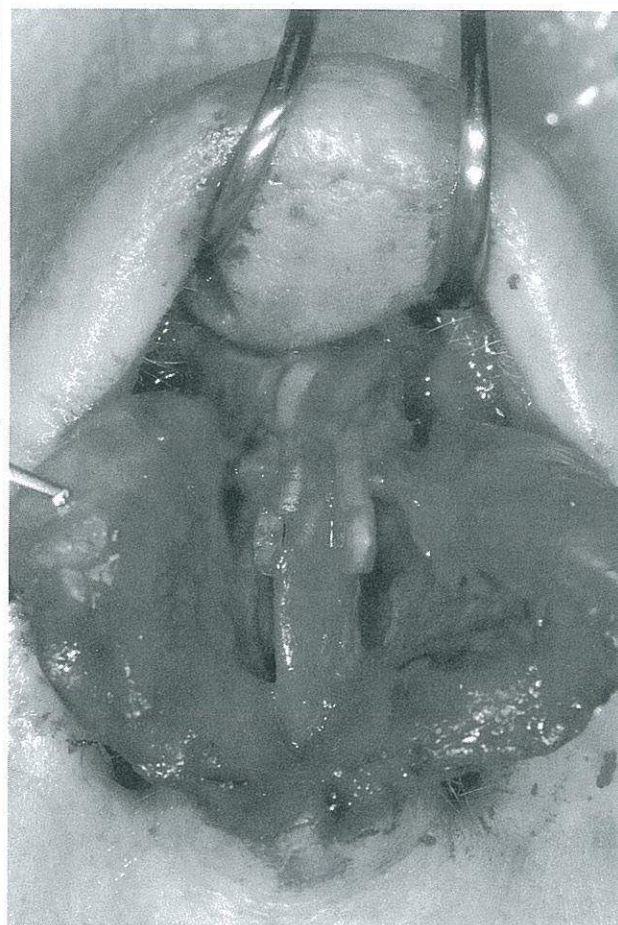


Figure 3 • Spreader grafts: bilateral cartilage strips sutured between the upper lateral cartilage and the quadrangular cartilage.

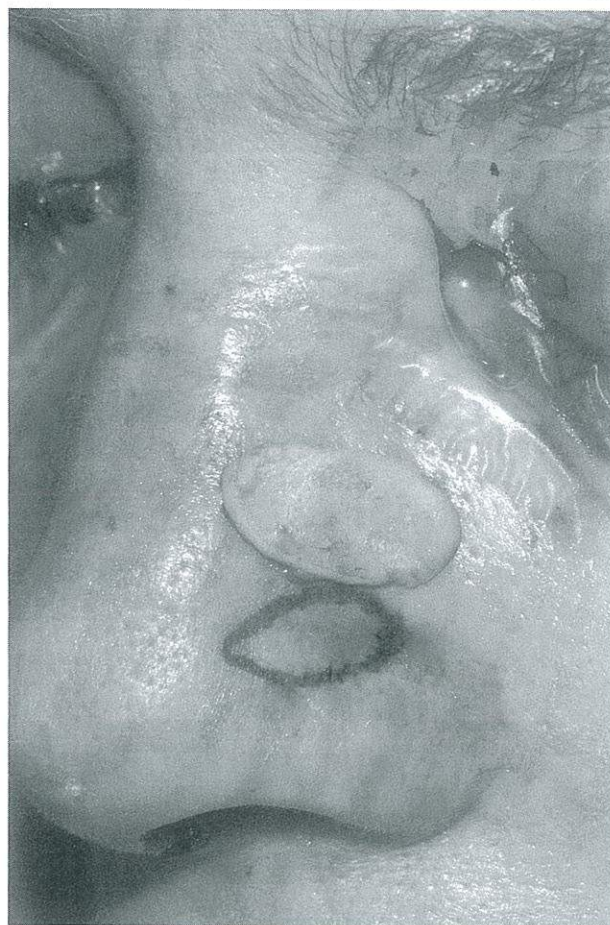

Figure 4 • Alar batten graft and outline of recipient site.

the area of structural deficiency after rhinoplasty in which excess lower lateral cartilage has been resected. The more concave portion of the graft is positioned medially to counteract the forces of collapse during nasal inspiration. In most cases, alar batten grafts also create fullness or convexity at the site of the graft that tends to decrease as edema resolves and scar contracture compresses and shifts the graft medially.

Some patients may present with a widened columella (Fig. 5). Although a widened columella alone is not usually the sole source of nasal obstruction, it can contribute to obstruction when other conditions such as external nasal valve collapse or caudal septal deviation are present. Septoplasty and caudal trimming alone do not correct this condition. There is often excess width of the posterior septal angle; this cartilage can be trimmed to allow the medial crural footplates to medialize. After the soft tissue is removed, the footplates of the medial crura must be brought to the midline with a suture placed bilaterally through the nasal vestibule.

Turbinate hypertrophy may also narrow the nasal airway sufficiently that treatment is required. The

narrowest area of the nasal cavity is in the most anterior aspect of the internal nasal valve. Aggressive inferior turbinate resection beyond its anterior third rarely results in improvement in the cross-sectional area of the nasal cavity. Moreover, resection of the majority of the inferior turbinate places the patient at risk for atrophic rhinitis.

In indicated patients with inferior turbinate enlargement who fail to respond to, or are intolerant of, nasal steroid sprays or oral decongestants, surgical management of the inferior turbinates may be indicated. A number of surgical treatment options exist, but all can be classified into one of three categories, depending on the tissue layer treated. The first is *submucous resection* of the inferior turbinate bone, which often results in expansion of the nasal airway. The turbinate is incised along its anterior head or inferior margin, and the submucosal bone is resected. A second option is *destruction* of the inferior turbinate mucosa, typically performed with one of a variety of lasers or exfoliative chemicals. These treatments destroy the epithelium and underlying glandular structures, thereby causing fibrosis of the layers. Both resection and destruction can put patients at significant risk for atrophic rhinitis, particularly those living in drier, cooler climates. The third and more recent approach is to target the *vascular erectile* tissue of the inferior turbinate while leaving the overlying mucosa largely undisturbed. This technique can be performed either with electrical energy (needle point cautery or radiofrequency ablation) or with a soft tissue shaver. The latter yields a predictable and immediate reduction in size of the inferior turbinate while preserving its humidification and secretory functions.

Middle turbinate enlargement rarely contributes to nasal airway obstruction. The increase in size is typically due to pneumatization of the anterior and inferior portion of the turbinate and is known as concha bullosa (Fig. 6). Such a phenomenon is usually seen in association with septal deflection to the contralateral side, and maximization of the nasal airway may require addressing both condi-

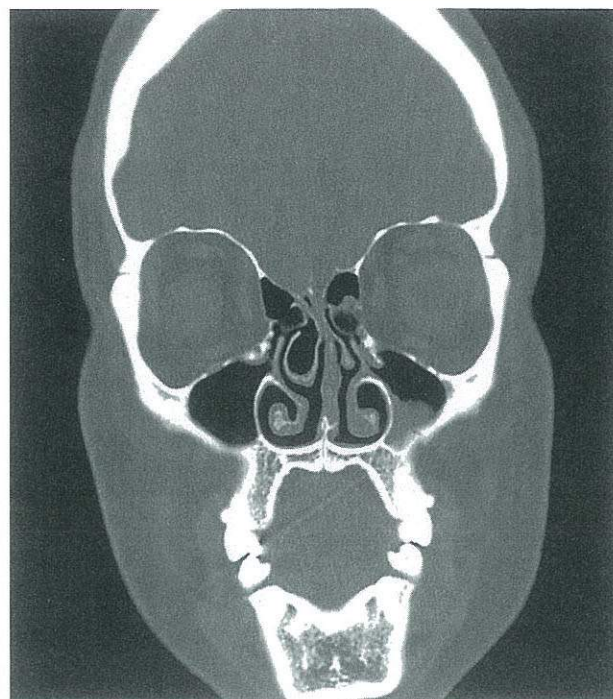


Figure 6 • Coronal computed tomographic image demonstrating concha bullosa involving the right middle turbinate.

tions. Correction of the septal deflection alone might result in lateralization of the enlarged middle turbinate and compromise of anterior ethmoid and maxillary sinus outflow. Simple crushing of the concha bullosa may instead lead to mucociliary obstruction. Removal of one of the lamellae of the concha is consequently the preferred technique.

Synechiae can be another problematic cause of nasal obstruction. They can result from recurrent intranasal infections or previous trauma, but the majority are secondary to iatrogenic trauma that occurs during septoplasty and nasal surgery. The surgeon should handle the septal flaps delicately at all times to prevent tears in the mucosa. It is critical that one dissect the mucoperichondrial flap below the perichondrium to maximize flap strength and thickness. Whenever there is concern that the raw surfaces of the turbinates are going to be in contact with the septum, it is wise to place a thin intranasal septal splint.

Complications

Complications after nasal airway surgery are not common. Postoperative infection is infrequent, and bleeding is uncommon as well. A small rolled piece of Telfa gauze in each nasal airway helps to stent the airway and absorb any blood from the nasal surgery. A nasal drip pad is routinely applied for the

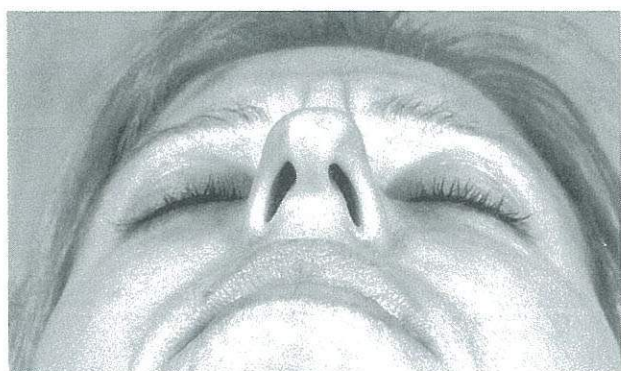


Figure 5 • Widened medial crural footplates contributing to obstruction of the external valve.

first 24 hours after surgery. Extensive full packing of the nose is rarely necessary.

Most complications of nasal airway surgery are not immediately apparent but, instead, manifest weeks after surgery when intranasal swelling has decreased and it is evident that the airway has not been improved. This is usually the result of a technical error in the operation. Failure to diagnose the condition preoperatively can also contribute to surgical failure. Often, failure to improve a patient's airway is the result of an inappropriate operation. Placement of inadequate spreader grafts or undersized battens can also lead to poor outcomes. Attention to detail in every step of the patient's preoperative evaluation, operative procedure, and postoperative care is the surgeon's best tool to prevent unsuccessful outcomes.

Pearls and Pitfalls

- Understand that nasal obstruction is secondary not only to deviated septa and enlarged turbinates but also to the more dynamic structures of the internal and external nasal valves. These four structures must be routinely and individually evaluated.
- Perform a complete physical examination. Direct observation of the patient's nasal respirations—both quiet and vigorous—helps to elucidate the causes of nasal obstruction. Avoid the temptation to proceed immediately to nasal speculum anterior rhinoscopy and spend a suf-

ficient amount of time meticulously inspecting the four main anatomic structures that affect the nasal airway.

- During surgery, handle nasal tissues with care and delicacy. Carefully dissect the mucoperichondrial membranes. Expose all septal irregularities (cartilaginous and bony), and close all tissues meticulously.
- Place a supportive dressing on the nose to allow for soft tissue stabilization as the grafts heal.
- Monitor patients long-term because postoperative nasal obstruction may take weeks to manifest.
- Both functional and aesthetic nasal operations should routinely include techniques that maintain or improve the airway.

SUGGESTED READINGS

- Constantian MB, Clardy RB: The relative importance of septal surgery and nasal valvular surgery in correcting airway obstruction in primary and secondary rhinoplasty. *Plast Reconstr Surg* 98:38-54, discussion 55-58, 1996.
- Gordon ASD, McCaffrey TV, Kern EB, Pallanch JF: Rhinomanometry for preoperative and post-operative assessment of nasal obstruction. *Otolaryngol Head Neck Surg* 101:20-26, 1989.
- Sheen JH: Spreader graft: A method of reconstructing the roof of the middle nasal vault following rhinoplasty. *Plast Reconstr Surg* 73:230-239, 1984.
- Toriumi DM, Becker DG: *Rhinoplasty Dissection Manual*. Philadelphia, Lippincott Williams & Wilkins, 1999.
- Toriumi DM, Josen J, Weinberger M, Tardy ME Jr: Use of alar batten grafts for correction of nasal valve collapse. *Arch Otolaryngol Head Neck Surg* 123:802-808, 1997.