

# Scar Revision and Camouflage

J. Regan Thomas

Steven Ross Mobley

## Key Points

- The ideal scar is narrow, flat with surrounding skin, parallel to the relaxed skin tension lines (RSTLs), or camouflaged within natural anatomic lines.
- Available scar revision techniques include excision, irregularization (including Z-plasty, W-plasty, and geometric broken line closure (GBLC), and dermabrasion.
- Adjunctive techniques include steroid injection, silicone sheeting, and cosmetics.

The head and neck is a prominent part of the human body and can frequently be injured as a result of trauma, burns, or surgery. With superficial injuries, most facial wounds will heal with little to no scar formation. However, once the reticular dermis has been violated, some amount of residual scarring is destined to occur. Several factors that are beyond the surgeon's control can affect the final appearance of the scar, including the mechanism of injury, position of the wound, health status of the patient, the patient's skin type, and the tendency to form robust scars. Factors that are under the surgeon's control include proper realignment of wound edges, conservative débridement of injured tissues, meticulous handling of tissues during primary repair, and aesthetically favorable alignment of scars whenever possible.

After complete maturation and healing, an ideal scar should be flat and level with the surrounding skin, a good color match with the surrounding skin, narrow, parallel to the RSTLs (Fig. 21-1) or on the border of aesthetic facial subunits, and without straight, unbroken lines that can be easily followed with the eye (Fig. 21-2).<sup>1</sup> Scars with aesthetically unfavorable characteristics include those that are wide or misaligned with relaxed skin tension lines or aesthetic subunits, and those that are thickened, hypertrophied, or keloid (Fig. 21-3).<sup>1</sup> The facial plastic surgeon has many options to improve, but not eliminate, these aesthetically unfavorable scars. Successful application of various treatments requires an understanding of which techniques are best indicated when performing scar revision or treating hypertrophic and keloid scars.

Successful scar revision begins with a precise analysis of both the scar and the patient's expectations. Patients often have the false perception that plastic surgery can make an existing scar invisible. The surgeon should educate the patient on the true realistic goal of surgery, which is to modify the scar to a point of maximized camouflage within the natural shadows, lines, and borders that exist within the head and neck.

## Indications for Revision

The surgeon should first begin with a detailed analysis of the scar. Experience has shown that many scars that are narrow, well positioned along aesthetic subunit borders, or in parallel with RSTLs will continue to mature, improve, and become less noticeable over a period of 12 to 36 months.<sup>2</sup>

More commonly, patients will have scars that are amenable to improved surgical camouflage. Indications for scar revision include scars that are (1) widened, (2) perpendicular to RSTLs, (3) webbed,

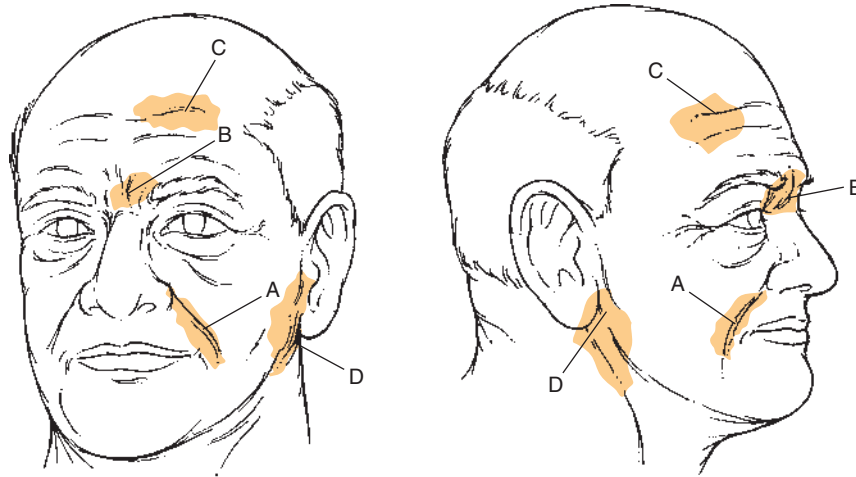
(4) pin-cushioned, (5) long and linear and misaligned with RSTLs, (6) hypertrophied, (7) interrupting an aesthetic unit of the face, (8) adjacent to, but not lying within, a favorable site, or (9) causing distortion of facial features or anatomic function. Many of these scars should be considered for revision after the first 60 to 90 days of scar maturation has occurred. In fact, early revision with realignment of the scar may allow it to mature more rapidly.

Numerous techniques are available when planning scar revision. This chapter organizes the techniques into the following categories:

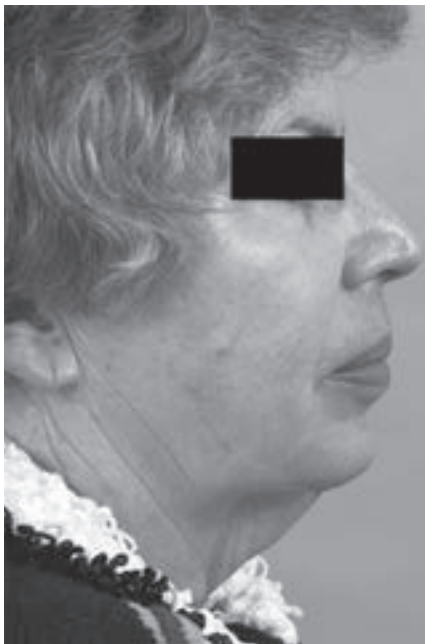1. Excision
2. Expansion with excision
3. Irregularization
4. Dermabrasion
5. Steroids
6. Silicone sheeting
7. Adjunctive

## Excision

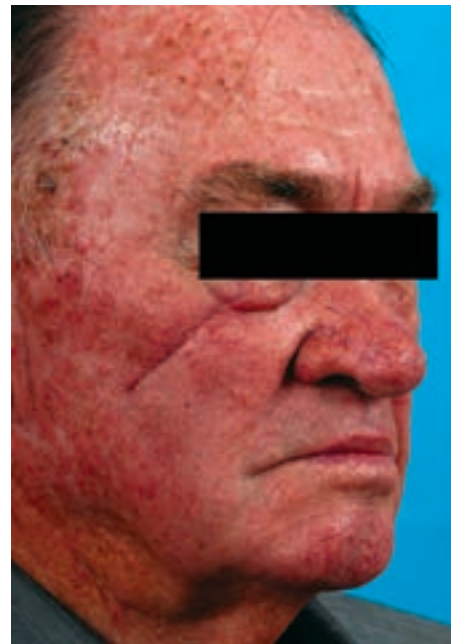A cardinal principle of surgery is that the best treatment of any complication is primary prevention. For scar revision, this translates into the use of proper technique when closing any wound primarily. When presented with wounds that were not closed properly, re-excision with meticulous closure may be all that is needed. Re-excision should be done by use of fusiform shape with 30-degree angled ends positioned within RSTLs when possible (Figs. 21-4 and 21-5). A slight vertical bevel outward from the original scar will prepare the wound edges for proper everted closure. Routine undermining of 1 to 2 cm around the periphery of the wound allows reapproximation of the skin edges with minimal tension. The use of buried subcutaneous sutures further decreases wound edge tension. Final eversion of the wound edges is achieved with properly placed monofilament interrupted sutures. Vertical mattress sutures can also prove helpful when wound edge eversion needs to be maximized.



**Figure 21-1.** Relaxed skin tension lines and creases can aid in scar camouflage. **A**, Nasolabial. **B**, Glabellar furrows. **C**, Horizontal forehead rhytids. **D**, Subunit junctions (ear and cheek). (Adapted from Thomas JR, Holt GR. *Facial Scars, Incisions, Revision & Camouflage*. St. Louis: Mosby; 1989.)



**Figure 21-2.** A 4-cm-long incision placed in alignment with relaxed skin tension lines and closed with multilayered closure and vertical mattress sutures.



**Figure 21-3.** Scar on right cheek with unfavorable characteristics: depressed and not in alignment with relaxed skin tension lines.

## Expansion with Excision

### Serial Excision

Wide scars, birthmarks, and skin grafts with poor match to surrounding tissues can all be candidates for serial excisions. In some ways, this is a variant of tissue expansion in that scarred skin is excised and adjacent normal skin brought into the defect area. Like tissue expansion, this technique relies on the skin's biologic creep (ability to stretch over time) and is limited by the given amount of stretch attainable during each excision. Typically, older patients and those with increased skin laxity will require fewer excisions than younger patients with increased skin tone. As with all techniques of scar revision, the patient must be well informed as to the proposed number of excisions and must understand that serial excision can require months to years to complete.

### Tissue Expansion

When treating larger scars, the best camouflage is afforded when abundant amounts of similar-appearing tissue can be brought into the repair.


Tissue expansion can be a powerful tool to help create excess amounts of surrounding tissue. Tissue expanders are available in a variety of shapes and sizes. Studies on the gain of surface area afforded by the three most commonly shaped expanders have determined that rectangular expanders provide the greatest expansion at 38%, crescent-shaped expanders provide 32%, and round expanders provide only 25%.<sup>3</sup> As a general rule, the base of an expander should be approximately 2.5 to 3 times as large as the area to be reconstructed.<sup>4</sup>

The effects of tissue expansion on skin have been debated. Is new skin actually produced or is the existing skin simply thinned and stretched? The currently accepted understanding regarding tissue layer expansion is that (1) the epidermis is thickened, (2) melanin production increases, (3) mitotic activity increases, (4) dermis thins (30% to 50%), (5) collagen synthesis is enhanced, (6) hair follicle number remains unchanged, (7) hair density decreases, (8) muscle thins and can atrophy, and (9) blood vessels proliferate.<sup>5</sup> Interestingly, epidermal changes and increased melanin production seen during expansion resolve a few months after surgery.

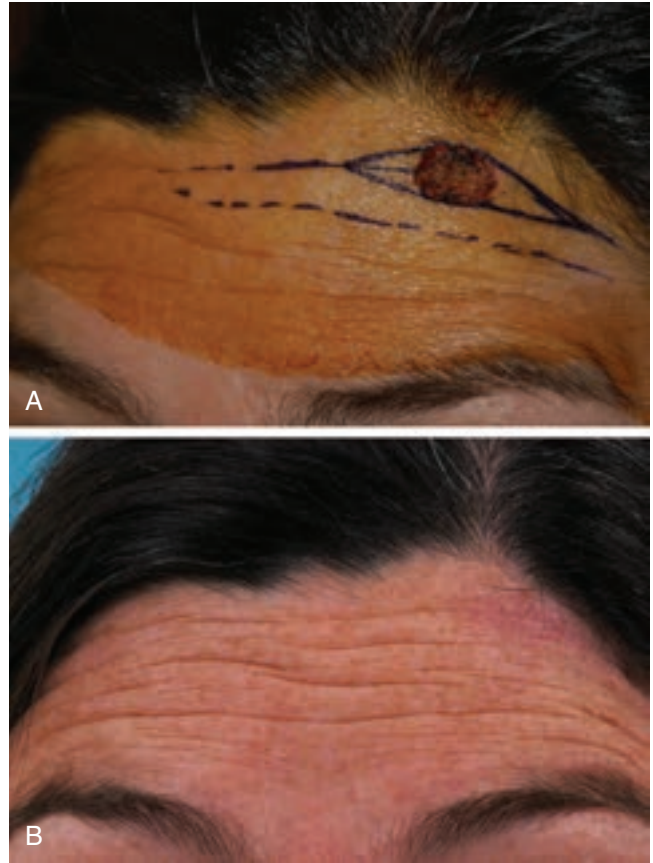Implantation of the expanders must take into account the neurovascular supply and final positioning of the skin to be transferred. A second pocket is created for the injection port, which should be several centimeters away from the expansion device and in an area that is easily accessed. Expander systems with external injection ports may be needed in select patients. A 23-gauge or smaller needle is used to inject the expander. Expansion can proceed until the skin blanches or the patient complains of discomfort. Intervals between injections can be from 4 to 14 days, ideally two to three times per week. By properly selecting the correct expander device and understanding the principles of tissue expansion, reconstruction of larger and more complex scars can be successfully achieved.

A critical point of understanding for the clinician is the temporary psychological toll that is placed on the patient undergoing expansion. Tissue expanders can cause impressive disfigurement of the head and

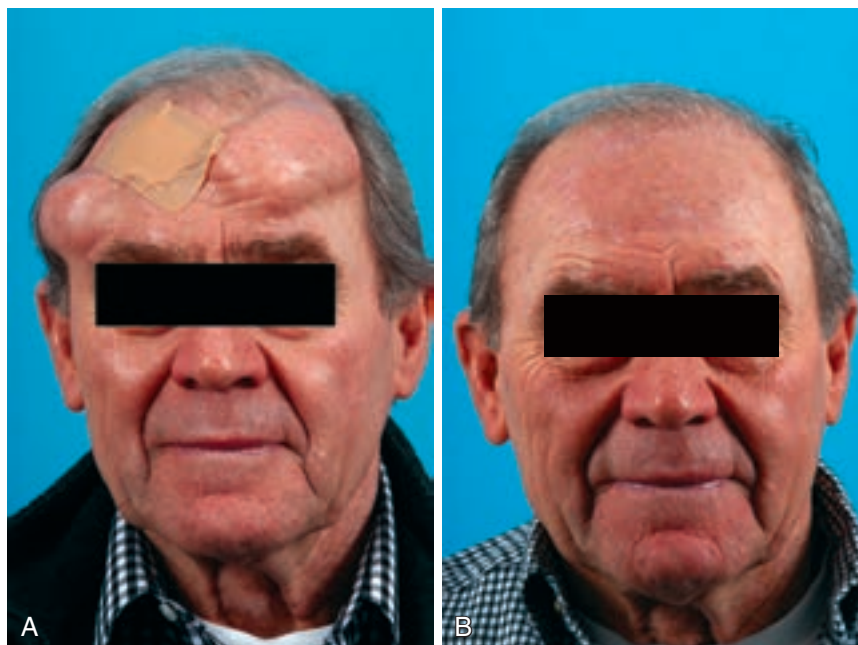
neck, which naturally results in significant emotional stress to the patient (Fig. 21-6A). Repeated acknowledgment and affirmation of the patient's uneasy feelings regarding the appearance of the expanders help support the patient throughout the expansion process. It is helpful to remind the patient that the disfigurement is temporary and that the



**Figure 21-4.** Examples of proper placement of fusiform incisions with 30-degree angled ends aligned with relaxed skin tension lines and aesthetic unit boundaries. (Adapted from Thomas JR, Holt GR. *Facial Scars, Incisions, Revision & Camouflage*. St. Louis: Mosby; 1989.)



**Figure 21-5.** **A**, Design of fusiform closure of Mohs defect. Note the design of a longer scar in parallel with relaxed skin tension lines to achieve 30-degree angles. **B**, Same patient 1 month postoperatively.



**Figure 21-6.** Patient midway (**A**) through process of bilateral forehead tissue expansion to close a Mohs defect in the forehead, and after (**B**).

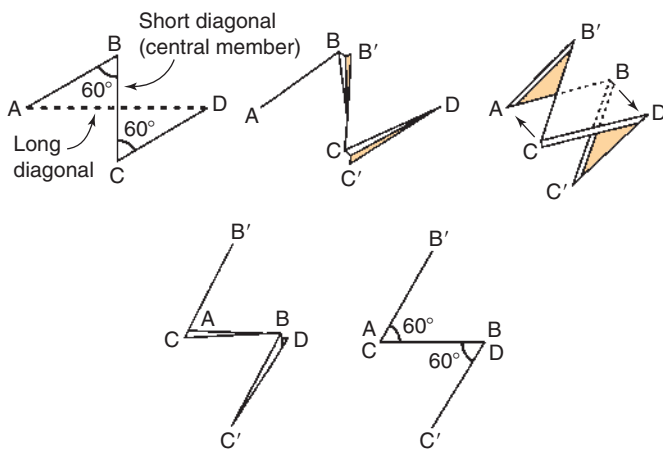
final reconstruction will warrant the time spent dealing with the expansion devices (see Fig. 21-6B).

## Irregularization

The human eye is more likely to perceive scars that are long, linear, and not in alignment with RSTLs and aesthetic subunits. To best camouflage these types of scars, the three most common techniques are Z-plasty, W-plasty, and geometric broken line closure (GBLC). All three of these techniques convert linear scars to irregularized zigzagged scars that are less noticeable to the casual observer. When irregularization alone is needed, GBLC and W-plasty are the treatments of choice. However, when both irregularization and lengthening of the scar are needed, a Z-plasty technique is the technique of choice.

### Z-plasty

The Z-plasty is one of the oldest and simplest techniques for scar irregularization. A “classic” Z-plasty involves the transposition of equilateral 60-degree triangles (Fig. 21-7). When these triangular flaps are transposed and closed, the original direction of the scar is rotated, and the scar is lengthened by 75%. When lesser amounts of lengthening are required, a 30-degree or 45-degree Z-plasty can be used that will lengthen the scar by 25% and 50%, respectively. Longer scars may benefit from multiple Z-plasties. This can be particularly helpful when correcting scar contractures along anatomic concavities. Consecutive Z-plasties allow for the redistribution of forces more evenly along the



**Figure 21-7.** Classic equilateral triangle 60-degree Z-plasty. (Adapted from Thomas JR, Holt GR. *Facial Scars, Incisions, Revision & Camouflage*. St. Louis: Mosby; 1989.)

entire length of the scar and help camouflage the scar into the surrounding RSTLs (Fig. 21-8). Another common indication for multiple Z-plasties is when wounds or skin flaps have healed with a “pin-cushioned” appearance. Placing several small Zs around the perimeter of the wound allows interdigitation of flap with surrounding skin (Fig. 21-9). The resultant interdigitated skin edge provides excellent camouflage, especially if it is later treated with light dermabrasion.

### W-plasty

The most common application of W-plasty is when several Ws are used in series in a technique originally described by Borge as “running W-plasty.” This is a useful irregularization technique that often uses shorter limbs compared with Z-plasty and does not create lengthening of the scar.

The technique begins with the marking out of a series of consecutive triangles (Ws) along the wound or scar edge. The arms should be between 5 and 7 mm in length, and one arm of the triangle should be drawn in parallel to the RSTL (Fig. 21-10). After excision of the triangles, superficial undermining of adjacent tissues is performed, and the triangular shaped flaps are then imbricated. Care should be taken to preserve the subcutaneous scar tissue, because this can provide a stable bed for new scar healing. These wounds are also amenable to postoperative dermabrasion to further camouflage the wound.

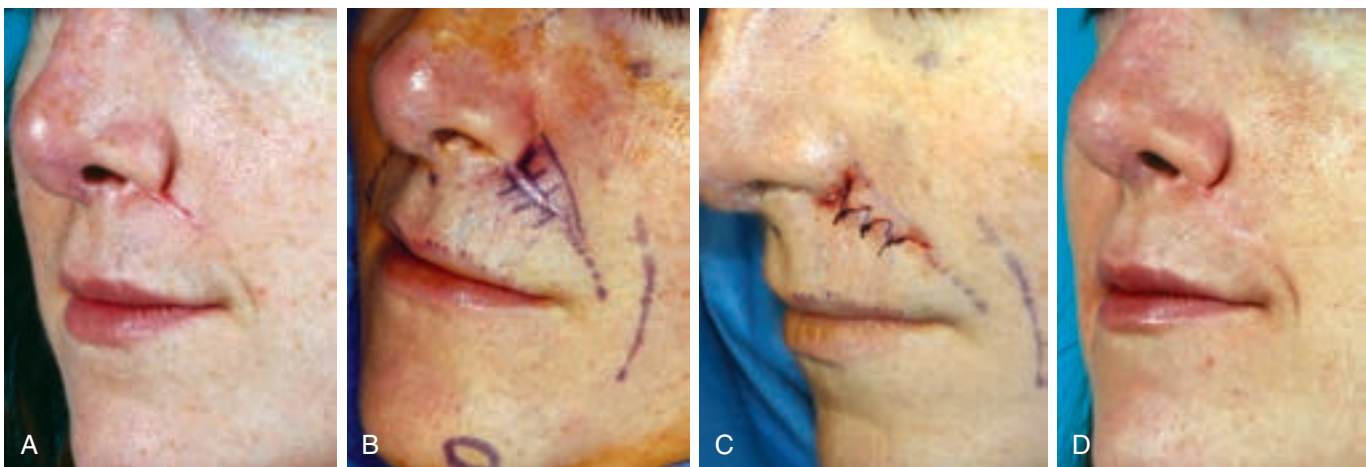
### Geometric Broken Line Closure

GBLC is an excellent technique of scar revision that creates an “irregularly irregular” scar without affecting its length. The geometry of the resultant scar is less predictable by the casual observer’s eye and frequently goes unnoticed. This technique is particularly well suited to scars that traverse broad flat surfaces such as the cheek, malar, and forehead regions (Fig. 21-11).

The design of a GBLC is a series of random, irregular, geometric shapes cut from one side of a wound and interdigitated with the mirror image of this pattern on the opposite side (Fig. 21-12). As in running W-plasty, the length of the geometric shapes is between 5 and 7 mm. Principles of undermining and leaving deeper scar tissue in the bed of the wound are similar to those previously described. Two-layered closure is performed, and the suture line is often reinforced with adhesive medical strips. The patient is typically seen back in 1 week for suture removal, with repeat taping of the wound edges for the next 2 weeks.

### Dermabrasion

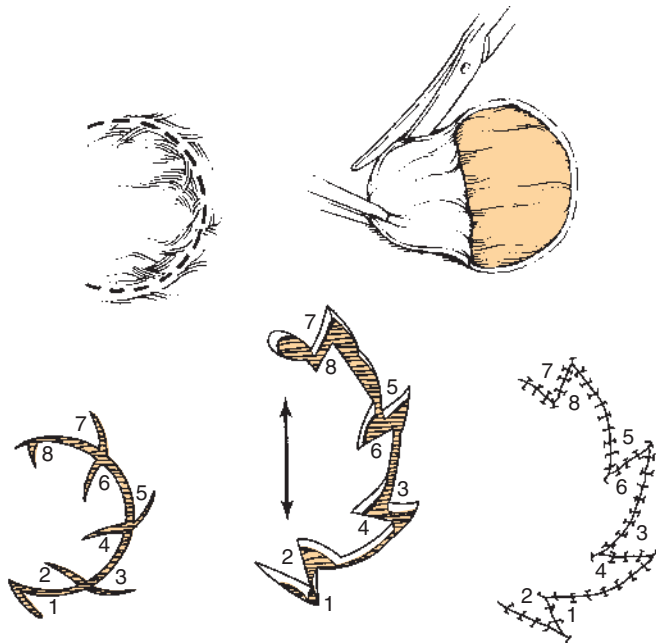
Dermabrasion is a method of controlled superficial skin ablation useful for smoothing out surface contour irregularities and softening the appearance of suture lines after primary closure or irregularization. We routinely use dermabrasion as a preplanned adjunctive procedure to any irregularization scar revision procedure. Dermabrasion is best per-



**Figure 21-8.** A, Preoperative appearance of scar on upper lip region. B, Operative plan for multiple Z-plasty technique. C, Appearance after transposition of Z-plasty. D, Postoperative appearance.

formed at the 6- to 8-week interval. There is evidence to suggest that rewounding during fibrillogenesis (i.e., 4 to 8 weeks after injury) may promote reaccumulation of hyaluronic acid in the wound matrix, thereby stimulating more epidermal cells to migrate and proliferate in the wound, improving the final appearance of the scar.<sup>6</sup>

The best candidates for dermabrasion are those with lighter complexions, because the risk of postabrasion dyspigmentation is lowest in these individuals. It is prudent to avoid dermabrasion in patients with human immunodeficiency virus or hepatitis because of the risks to health care personnel from airborne pathogens. The use of 13 cis-retinoic acid and its effect on healing after dermabrasion has been debated in the literature. Conflicting reports exist, and until the controversy is resolved, prudence would suggest waiting 6 to 12 months before performing dermabrasion on anyone with a prior history of 13 cis-retinoic acid use.<sup>7,8</sup> Patients with a history of herpetic infection should be placed prophylactically on antiviral therapy. Others have advocated placing all patients on prophylactic antivirals.<sup>6</sup>



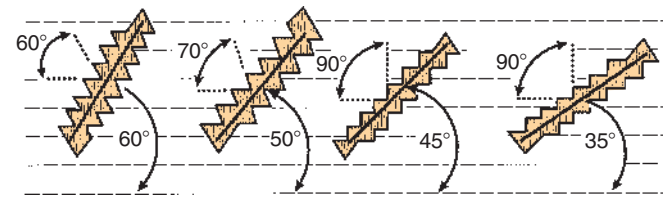
**Figure 21-9.** Multiple small Z-plasties to improve the appearance of circumferential or pin-cushioned scars. (Adapted from Thomas JR, Holt GR. Facial Scars, Incisions, Revision & Camouflage. St. Louis: Mosby; 1989.)

Diamond fraise bits are preferred, because they are easier to control and remove the skin less aggressively than wire brush fraises. The hand-piece is generally held 90 degrees to the direction of wheel rotation and is advanced at right angles to the direction of wheel rotation (Fig. 21-13). Preparation of the area to be dermabraded can be accomplished with local anesthesia both for nerve block and infiltration. Infiltration not only provides anesthesia but can also cause distention of the skin, which aids in the technique. Preferably, local anesthetic without epinephrine is used to allow for more clear visualization of capillary bleeding that is seen with dermabrasion. As one enters the superficial papillary dermis, small capillary loops are identified as pinpoint bleeding. As the papillary dermis is penetrated more deeply, small parallel strands of white-colored collagen can be appreciated. Once this is seen, dermabrasion is taken to the appropriate depth. Preservation of the reticular dermis with its adnexal structures allows for the proliferation of undamaged epidermal cells across the abraded surface. The periphery of the treated area should be feathered with fine diamond fraises to allow for a smooth transition between treated and untreated areas.

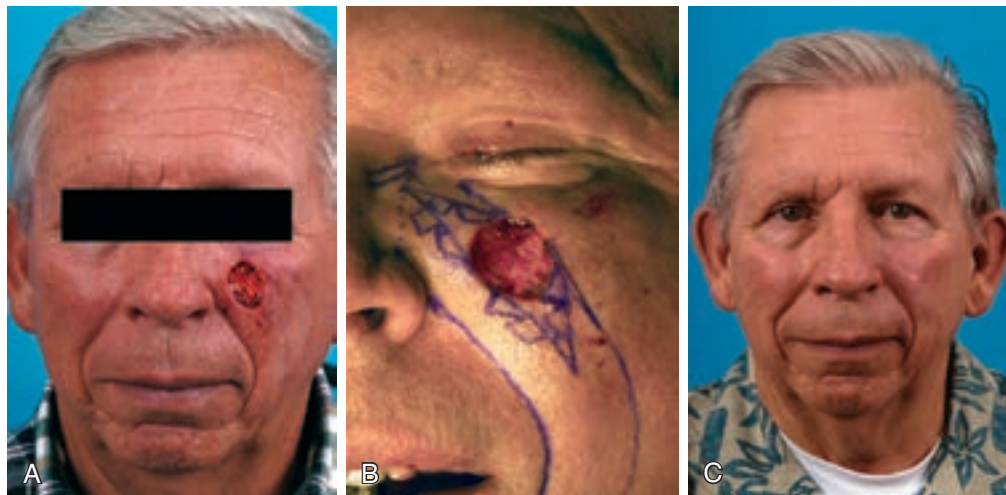Immediately after treatment, an occlusive dressing such as polyethylene oxide hydrogel (Vigilon) is applied. This is left in place for 48 hours, and then the patient is instructed to keep the area moist at all times with bacitracin for the next 7 to 10 days. After that, the patient can use a thick moisturizing lotion such as Eucerin. Re-epithelialization is usually accomplished after 5 to 7 days, but post-treatment erythema can often take 2 to 3 months before resolution (Fig. 21-14). This should be clearly communicated to the patient before the procedure. Women are usually less bothered by this, because they can begin to cover the area with make-up once re-epithelialization is complete.

**Steroids**

Intralesional corticosteroids can be an effective adjunct in the treatment of healing wounds, hypertrophic scars, and keloids. Steroid injections

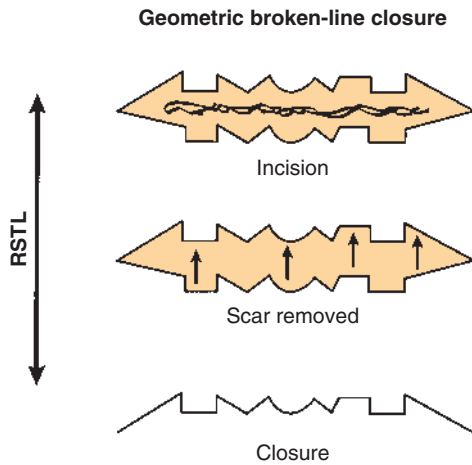


**Figure 21-10.** Running W-plasty with one area of triangle aligned in parallel with relaxed skin tension lines (RSTL). As scar inclination decreases, the degree of the angles should be increased to keep one arm of the triangle aligned with RSTL. (Adapted from Thomas JR, Holt GR. Facial Scars, Incisions, Revision & Camouflage. St. Louis: Mosby; 1989.)



**Figure 21-11.** A, Moderate-sized Mohs defect in the left cheek. B, Design of geometric broken line closure that is in parallel with relaxed skin tension lines. C, Several months postoperatively.

into areas of scar revision can be useful when persistent tissue edema detracts from the wound's appearance. Small doses of triamcinolone (10 mg/mL) injected into the dermis or the dermis subcutaneous junction can provide the surgeon with an ability to "sculpt" an otherwise normally healing wound and hasten the resolution of edema. For example, intralesional steroids can help lessen the "pin-cushion" edema seen frequently in local flap reconstruction techniques such as bilobed flap repair (Fig. 21-15). Steroids can cause hypopigmentation and telangiectasias when injected in higher concentrations into the dermis. One should avoid the injection of steroids into the subcutaneous fat, because this can lead to deformity from fat atrophy. Judicious use and



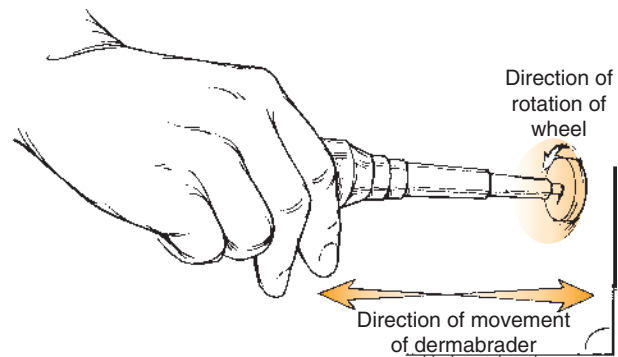
**Figure 21-12.** Geometric broken line closure irregularizes the scar to a less predictable pattern, further increasing camouflage. Note parts of geometric shapes in parallel with relaxed skin tension lines. (Adapted from Thomas JR, Holt GR. *Facial Scars, Incisions, Revision & Camouflage*. St. Louis: Mosby; 1989.)

conservative clinical judgment are usually all that is needed to prevent these untoward events.

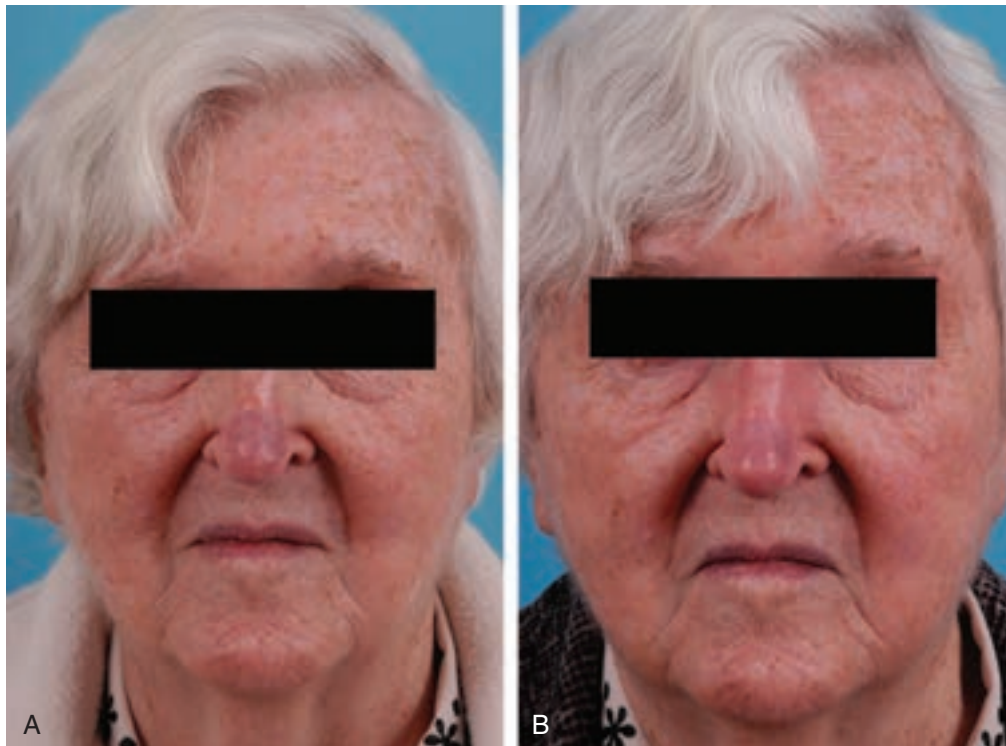Topical steroids can also be used when one is trying to diminish minor wound erythema that can be a normal part of the healing process. This has an application in younger patients and those with more sebaceous skin who are prone to erythematous wounds. Also, after dermabrasion of other resurfacing procedures, short-term low-dose topical steroids can be applied after re-epithelialization is complete.

### Silicone Sheeting

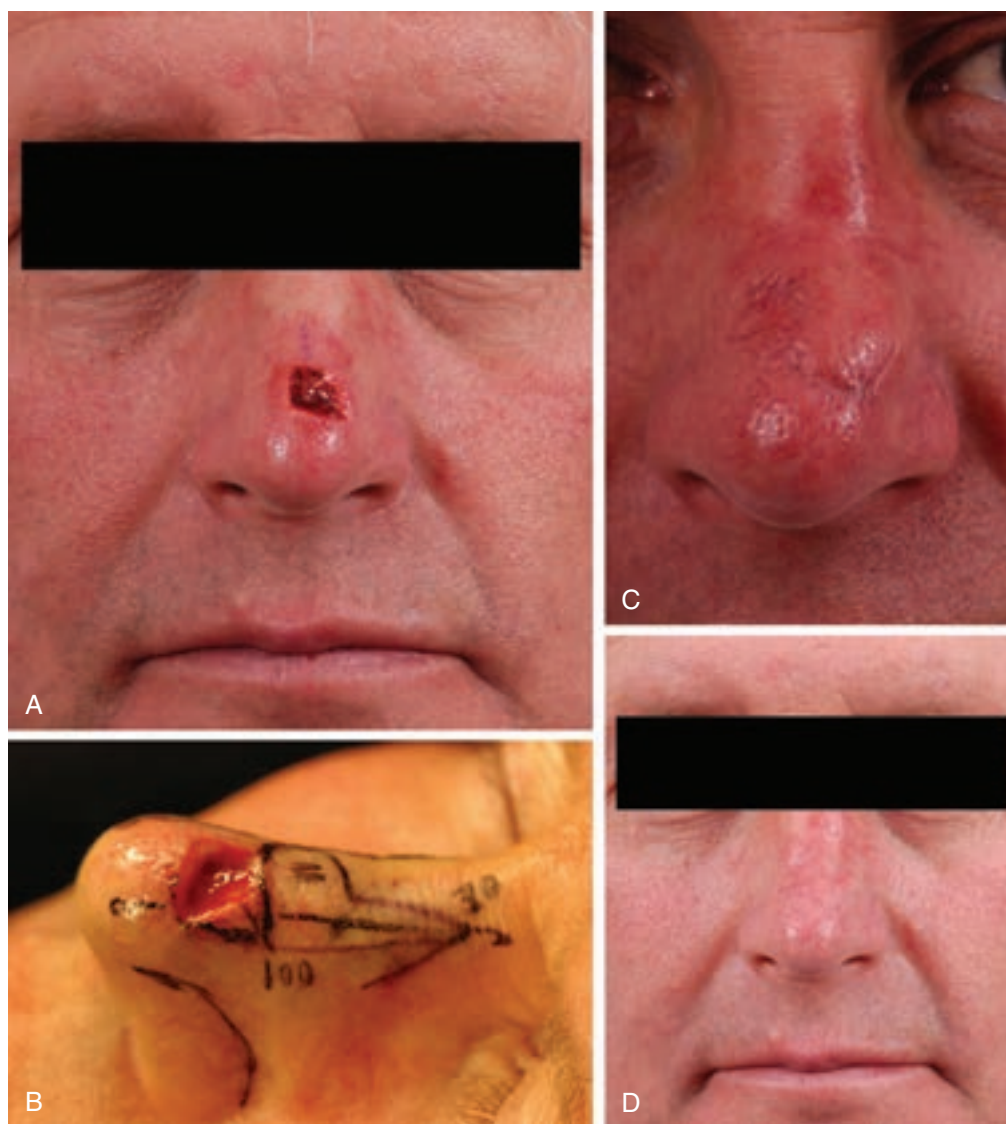The topical application of silicone gel sheets to the surface of keloids has been shown to be beneficial to the improvement of scars. Ohmori<sup>9</sup> studied the effects of silicone sheeting on 46 patients with 48 keloids in all areas of the body. By use of a study-defined grading scale, he reported excellent and good results in 60% of patients and fair to poor results in 40%. Katz<sup>10</sup> investigated the use of silicone sheeting for both



**Figure 21-13.** Dermabrader moved at right angles to direction of wheel rotation. (Adapted from Thomas JR, Holt GR. *Facial Scars, Incisions, Revision & Camouflage*. St. Louis: Mosby; 1989.)



**Figure 21-14.** A, Patient 6 weeks after full-thickness skin graft to nasal tip. B, Same patient 1 month after dermabrasion of entire nasal aesthetic unit.



**Figure 21-15.** **A**, Patient with Mohs defect of nasal tip. **B**, Intraoperative photo demonstrating design of flap; note the design of the second lobe to lie within aesthetic subunits of the nose. **C**, Three weeks postoperatively with typical “pin-cushion” edema seen with bilobed flaps. **D**, Three months postoperatively. Patient has received three subcutaneous injections of 10 mg/mL triamcinolone delivered 2 weeks apart.

keloids and hypertrophic scars. Fifty-six percent of keloids demonstrated measurable improvement. Zero of five patients with a history of hypertrophic scarring had recurrence of their hypertrophied scars after excision and postoperative silicone sheeting. Typically, patients are encouraged to wear the silicone for a minimum of 8 to 12 hours per day and to use it for 6 to 12 months. The use of topical silicone sheets should be considered in any scar that is not ideal secondary to being slightly raised or possessing hyperpigmentation.

The biophysical properties of silicone sheeting have been studied, but still the mechanism by which silicone sheeting may improve scar healing is not well characterized.<sup>11,12</sup> Changes in pressure, temperature, and oxygen tension have all been studied and found to be negligible. Silicone sheeting has been shown to increase scar hydration by reducing evaporation by more than 50%. This is postulated to cause a decrease in capillary activity and perhaps collagen deposition. It can be stated

with reasonable confidence that silicone sheeting seems to have a favorable effect on wound healing and exposes the patient to little or no morbidity from the treatment.

## Adjunctive Procedures

### Cosmetics and Hairstyling

Although not routinely thought of as part of the medical management of scar revision, cosmetics and hairstyling can play an important role in these patients. Surgeons who routinely perform scar revision are encouraged to seek out aesthetic professionals in their area that have interest in helping with the care of these patients. The physician's familiarity with these adjunctive professional services is often met with great pleasure by the patient who is eager to look normal and regain confidence in his or her appearance.

For complete list of references log onto [www.expertconsult.com](http://www.expertconsult.com).