

# Extracorporeal Septoplasty

## Complications and New Techniques

Matt A. Wilson, MD; Steven R. Mobley, MD

**Objectives:** To report our complication rates during extracorporeal septoplasty (ECS) and to describe a new fixation and splinting technique we developed to simplify stable midline fixation of the neocaudal septum. Correction of the caudally deviated septum remains one of the more difficult surgical goals in functional nasal surgery.

**Methods:** A retrospective medical record review of patients undergoing ECS at our institution. We report our complications and describe a new technique for ECS.

**Results:** Forty-six patients underwent ECS from June 1, 2007, through April 30, 2010. Twenty-six of these pa-

tients underwent primary surgical repair, whereas 20 presented for revision surgery from outside facilities. Ten revision cases required an ear cartilage graft, and 5 required a rib graft. The overall complication rate was 9% (4 patients), with 4% (2 patients) each for minor and major complications.

**Conclusions:** Complication rates of ECS are similar to those of endonasal septoplasty. Stable midline fixation of a reconstructed neocaudal septum is possible with a new technique that relies on novel splinting instead of suture fixation to the midline of the nasal spine.

*Arch Facial Plast Surg. 2011;13(2):85-90*

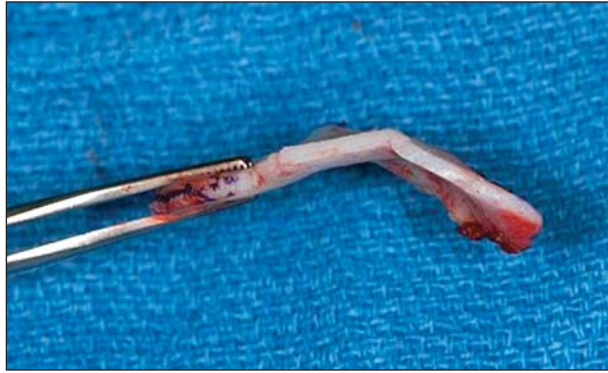**A**T LEAST 3 VARIATIONS OF caudal septum deviation can be diagnosed by means of anterior rhinoscopy and further detailed by gloved palpation with the thumb and forefinger. The first type is when the caudal septum itself is palpated to be relatively straight from the anterior septal angle to the posterior septal angle but the posterior septal angle has slipped off the nasal spine and thus protrudes off the midline into the caudal nasal passageway. In these cases, the caudal septum can frequently be brought back into the midline with a relatively straightforward endonasal septoplasty using a “swinging door” technique.<sup>1</sup> The second variation is when the septum comes off the nasal spine at an angle of greater than 30° in the axial plane. On palpation, the septum may be flat or cup shaped. In these more extreme septal deformities, it can be difficult to address the septum by conventional open or endonasal methods, and thus an extracorporeal technique may be more appropriate. The final and perhaps most challenging variation of caudal septal deformity is when the surgeon appreciates that the caudal septum is not straight from the anterior to the posterior septal angle but rather feels like a curved bowl or a C-shaped septum between the thumb and forefinger. Extracorporeal septoplasty (ECS) is particularly helpful in these cases because, without building

a neocaudal septum, the cup-shaped curvature is difficult to correct surgically or will frequently return postoperatively.

Extracorporeal septoplasty for correction of the severely deviated caudal septum was first reported by Gubisch<sup>2</sup> in 1995. He described complete removal of the entire cartilaginous septum, which he then straightened and returned to the nose. He described 2 areas of fixation to secure the newly reconstructed septum back into the native nose. The first area of fixation is the caudal end of the nasal bones, where the cephalic dorsal septum is reattached. He accomplished this by suturing the reconstructed septum to the upper lateral cartilage or by placing a transcutaneous U-suture. The second point of fixation is the maxillary crest, where the posterior septal angle is reattached. He accomplished this by drilling a hole through the nasal spine and suturing the newly reconstructed neocaudal septum down to the maxillary crest. Although this technique was highly effective for straightening a deformed septum and replacing it in the nose to restore nasal function, it has been criticized for being very technically demanding to execute. There was also a risk of aesthetic complications, especially in the area of transition from the bony dorsum to the reconstructed cartilaginous dorsum.

In 2006, Most<sup>3</sup> modified Gubisch’s technique<sup>2</sup> to simplify the reconstruction and decrease the aesthetic complications along

**Author Affiliations:** Division of Otolaryngology–Head and Neck Surgery, University of Utah School of Medicine, Salt Lake City.



**Figure 1.** Septal cartilage removed from the nose. Caudal deviation of greater than 30° is seen.

the bony and cartilaginous dorsum. Most<sup>3</sup> described excising almost all of the cartilaginous septum (as Gubisch<sup>2</sup> described), preserving a 1.5-cm dorsal septum remnant. He then sutured the reconstructed septum to whichever side of the dorsal remnant was more concave. Fixation in the area of the posterior septal angle to the nasal spine was performed similarly as described by Gubisch.<sup>2</sup> Most<sup>3</sup> achieved functional results that were excellent, and he reported no aesthetic complications.

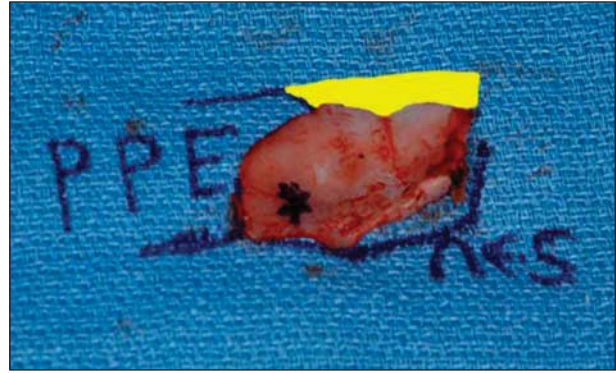
In an era in which outcomes data are growing increasingly critical, little is known about the complications of ECS because only a few articles have published such data. The majority of data regarding complications with this technique are from Gubisch's experience.<sup>2</sup> Data describing the complications using the modified technique by Most<sup>3</sup> are limited to only 37 patients in 2006. Because ECS is a newer and evolving technique, it is crucial that more results be published describing its associated complication rates so that safety, efficacy, and outcomes can be more easily determined by a review of the literature.

We report our complications with ECS and discuss a new technique that simplifies the overall procedure by eliminating suture fixation of the neocaudal septum to the nasal spine as described by Gubisch<sup>2</sup> and Most.<sup>3</sup>

## METHODS

Institutional review board approval was obtained by the University of Utah review committee. A retrospective medical record review was conducted for all patients undergoing ECS by one of us (S.R.M.) from June 1, 2007, through April 30, 2010. This author has developed a busy multistate referral practice for complicated and severely deformed nasal septums. A stringent patient selection process was used. Patients selected for the ECS technique had a C- or cup-shaped septum and/or the septum came off the nasal spine at an angle of greater than 30° in the axial plane. Data reviewed included age, sex, follow-up, complications, primary vs revision surgery, and graft materials.

We categorized our complications into 2 groups. Major complications were classified as those necessitating additional surgical therapy. Minor complications required no further surgical intervention. In this study, all patients in the minor complication category presented to the office with erythematous columellar incisions and were treated aggressively with a course of oral antibiotics. No patients in the minor complication category had a true frank infection (or abscess) as defined by fever or exudate from the external incision.



**Figure 2.** Septal cartilage before reconstruction with a diagram of the original anatomy. NES indicates nasal spine; PPE, perpendicular plate of the ethmoid; yellow, the 1.0-cm dorsal remnant left behind. \*Posterior border of the native cartilage.

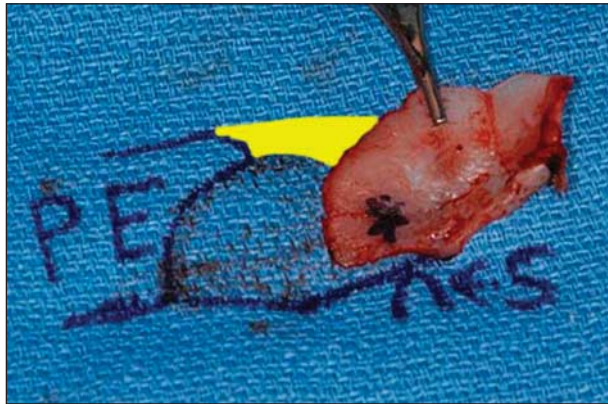
All patients are treated with perioperative intravenous antibiotics. Cefazolin sodium (Ancef), 1 to 2 g, or clindamycin phosphate (Cleocin), 600 to 800 mg, if the patient is allergic to penicillin, is administered according to the patient's body weight. Antibiotic therapy is continued postoperatively in prophylactic doses with cephalexin (Keflex), 250 mg 4 times per day, or clindamycin hydrochloride, 150 mg 4 times per day, for 5 days.

The initial exposure of the septum is an external rhinoplasty approach in all cases. The domes are divided in the midline, and the upper lateral cartilages are released laterally, creating excellent exposure of the septum. Bilateral submucoperichondrial flaps are elevated, exposing the entire cartilaginous and anterior bony septum. The majority of the cartilaginous septum is then resected (**Figure 1**). The amount of dorsal remnant left behind is ideally 1 cm or more but can vary from 1.5 cm down to as little as 0.8 cm in cases of severe high dorsal deviation<sup>3</sup> (**Figure 2**).

The septum is then reconstructed on the back table. At this point it is determined whether additional cartilage is needed. If only a small amount of nonstructural supportive cartilage is required, then an ear cartilage graft is obtained. If there is insufficient septal cartilage and more rigid or strong cartilage is needed for structural support, then a rib cartilage harvest is performed. These autologous grafts, when necessary, are then used to complete the neoseptum reconstruction; once this is completed, the neoseptum is brought back into the native nose.

One key element to our technique is the anterior to posterior (cephalocaudal) length of our reconstructed neoseptum. The reconstructed septum is fabricated such that the caudal edge of the neocaudal septum spans the membranous septum and ends caudally flush with the caudal edge of the medial crural cartilages, a key anatomical point (**Figure 3**).

Once the distorted and crooked septum is reconstructed and straightened on the back table, we then proceed to fixation. Dorsal fixation is accomplished by placing the neocaudal septum on whichever side of the dorsal strut is most concave, as described by Most.<sup>3</sup> It is a surgical reality that most autologous grafts used for this technique—whether native septum or rib—are not completely straight and have a slight amount of natural curvature. The surgeon must study the reconstructed neoseptum closely to determine how this slight curvature can be used to ensure that the final reconstructed septum is in the midline of the nose. When internal valve compromise has been diagnosed preoperatively, we will place additional spreader grafts, which can also help to structurally hold the neoseptum in the midline. Sometimes all that is needed is a single spreader graft placed along the dorsal septum remnant opposite the side where the reconstructed septum was placed.



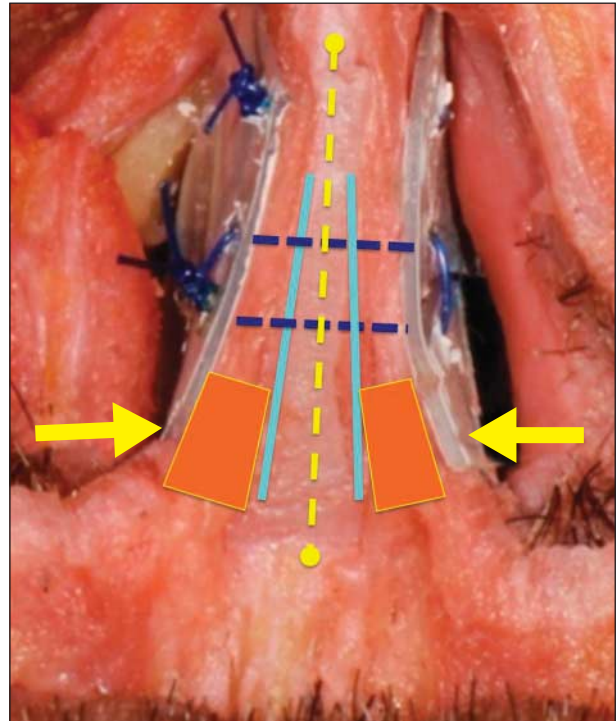
**Figure 3.** The neocaudal septum reconstructed from that seen in Figure 2 in its new position. It extends past the original caudal septum up to the level of the medial crura. NES indicates nasal spine; PE, perpendicular plate of the ethmoid; yellow, the 1.0-cm dorsal remnant left behind. \*Posterior border of the native cartilage.

We then proceed to caudal fixation. As mentioned, a key maneuver in our technique is the fabrication of a neocaudal septum that is longer (cephalocaudad) than the native septum and thus extends caudally across the membranous septum to the caudal edge of the medial crura. We then place 6-0 polydioxanone sutures through the vestibular epithelium of the medial crura, the neocaudal septum, and the contralateral medial crura vestibular skin and then back through all 3 structures to complete a mattress stitch.

We often finish the reconstruction by placing small patties (2-5 mm in diameter) of crushed cartilage around the posterior septal angle of the neocaudal septum where it is in close contact with the nasal spine, but again, no suturing to the nasal spine is needed.

Before closing the nose, plastic splints are placed along either side of the septum. The inferior and anterior edge of each splint is cut to fit securely along the floor of the nose and just alongside or slightly posterior to the medial crura cartilages. The splints are sutured into place with through-and-through 4-0 black nylon suture. Typically, 3 to 6 sutures are required for adequate fixation. We start by placing 1 or 2 sutures low on the splints. This tends to pull everything into the midline. We then place 1 or 2 sutures caudally, just behind the medial crura, for further caudal fixation. One or 2 additional sutures may be placed in the upper to middle body of the neocaudal septum to increase midline fixation and stability (**Figure 4**).

It is customary for all our patients to return the following day for a postoperative evaluation. Columellar sutures are removed 1 week postoperatively. The splints are usually removed at the 2-week postoperative visit. However, in a few cases of very high complexity, in which multiple grafts were sutured to one another on the back table in an effort to fabricate a neoseptum, the splints are left in place for 3 weeks. We remove the splints by first cutting the sutures with the tip of a No. 11 blade, with most of the body of the blade wrapped once with bandage tape to avoid accidental cutting of the inner nasal cavity. We then gently elevate the splint from the septum on both sides with a flat wax curette. The splint is then removed using a Kelly clamp in a 90° twisting motion. This technique has never compromised our repair, although if performed without care, it could damage the neoseptum. On 2 occasions, a patient has been unavailable for follow-up with splints in place, only to return 1 month and 5 months later. Their only complaint was excessive crusting. Even then the splints were easy to remove after the crusts were debrided.



**Figure 4.** Base view of the custom-cut nasal splints. Arrows indicate the vector of tension for midline fixation on the nasal spine.

## RESULTS

Forty-six patients underwent ECS from June 1, 2007, through April 30, 2010, at the University of Utah for correction of a severely deviated caudal septum. Twenty-six of these patients presented for primary surgical repair. Twenty patients presented for revision surgery from outside facilities. Ages ranged from 16 to 72 years, with an average age of 34 years. Most of the patients were male (male to female ratio, 38:8).

Forty-one patients (89%) were followed up within 2 days after surgery. All patients were followed up within the first postoperative week. All but 1 complication was discovered on routine follow-up examination.

None of the 26 primary surgical repairs required distant cartilage grafts. Fifteen of the 20 revision cases (75%) required a distant cartilage graft. Ten (50%) required an ear cartilage graft owing to lack of reconstructive material, and 5 (25%) required a rib graft owing to lack of ear cartilage or the need for inherently stronger cartilage for reconstruction. Only 5 revision cases (25%) had an adequate amount of septal cartilage to reconstruct the septum.

Four patients (9%) experienced a complication: 2 (4%) were minor and 2 (4%) were major complications. The complication rate of patients undergoing primary surgery was 4% (1 patient), which was a major complication. This patient developed a 2-mm septal perforation that was discovered 3 months after surgery. This perforation was closed in the operating room without difficulty but required an ear cartilage graft to aid in the closure. Patients undergoing revision surgery had a complication rate of 15% (3 patients). Two of these patients were treated with antibiotics alone and recovered without additional interven-



**Table. Complications of ECS**

Patient No.	Procedures With ECS	Primary vs Revision Surgery	Cartilage Graft	Complication	Treatment
1	Bilateral spreader graft Bilateral SMR	Primary	None	Minor infection	Antibiotic therapy
2	Bilateral spreader graft	Primary	None	Small septal perforation	Closure of septal perforation
3	Bilateral SMR Nasal wall reconstruction	Revision	Rib	Major infection	Antibiotic therapy; incision and drainage
4	Bilateral spreader graft	Revision	None	Minor infection	Antibiotic therapy

Abbreviations: ECS, extracorporeal septoplasty; SMR, submucous resection.

tion. One patient developed a more serious infection identified 3 weeks after surgery by an outside otolaryngologist. His incisions appeared normal at his 2-week postoperative appointment, at which time his splints were removed. He required incision and drainage of a septal abscess with placement of a Penrose drain. His functional and aesthetic results were not compromised (**Table**).

A few patients mentioned that they noticed nasal tip firmness after the procedure. We educate all our patients about the likelihood of nasal tip firmness, thus setting appropriate expectations. We also have this outcome listed in and discussed on our written risk and consent form. Because many of these procedures are performed for functional reasons, most patients are not concerned with nasal tip firmness.

#### COMMENT

Extracorporeal septoplasty is a newer, rapidly evolving technique. It was first discussed in the 1950s by King and Ashley.<sup>4</sup> Gubisch<sup>2</sup> was the first to publish a large series on the topic in 1995. That series included more than 1000 patients during a 15-year clinical experience. Two follow-up studies were performed in 1999<sup>5</sup> and 2005.<sup>6</sup> A few other authors have reported their cases, but there are still relatively few data about the complications of this surgical technique, especially with further application of some of the technique modifications described by Most.<sup>3,7,8</sup> As a new technique is introduced to surgeons and into the surgical literature, it is imperative to discuss various outcome measures. We describe the surgical outcomes after using this technique in our carefully selected patient population undergoing ECS.

Bloom et al<sup>9</sup> recently published a review article covering a large number of studies about the complications for endonasal septoplasty. The possible complications from a standard endonasal approach include hemorrhage or septal hematoma (6%-14%), cerebrospinal fluid leak (rare), infection (0.048%-2.5%), overcorrection (2%), septal perforation (1%-6.7%), adhesions or synechiae (7%), hyposmia (0.3%), and aesthetic deformities (4%-8%).<sup>9</sup> All these complications are also possible when performing the extracorporeal technique, but this study adds additional information to the literature regarding the risks of traditional septoplasty techniques compared with the more evolved technique of ECS. As mentioned previously, Gubisch<sup>2</sup> was the first to report his data. He reported a hemorrhage/septal hematoma rate of 0%,

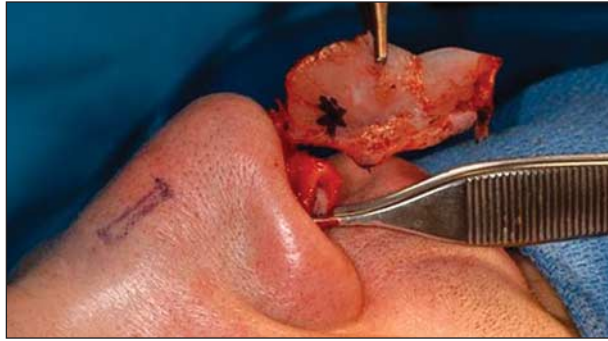
an infection rate of less than 1%, a septal perforation rate of less than 1%, and an aesthetic complication rate of 7% to 11%. Later, Most<sup>3</sup> reported his complication rate among 37 patients undergoing the modified technique as an astonishing 0% across the board.

We have attempted to divide our complications into major and minor ones. We had major and minor complication rates of 4% each. Our minor complications were limited to 2 patients who had erythematous columellar incisions and thus started a 5- to 7-day course of oral antibiotic therapy. None of these patients in the minor complication group had frank pus, purulence, or systemic fever. Our major complication rate was similar to that of endonasal septoplasty. Our septal perforation rate was 2%, and our major infection rate was also 2%; both rates are comparable to the risks of these complications for traditional septoplasty. No patients in our series experienced hemorrhage, septal hematomas, or aesthetic complications. All patients had subjective improvement in their nasal obstructive symptoms.

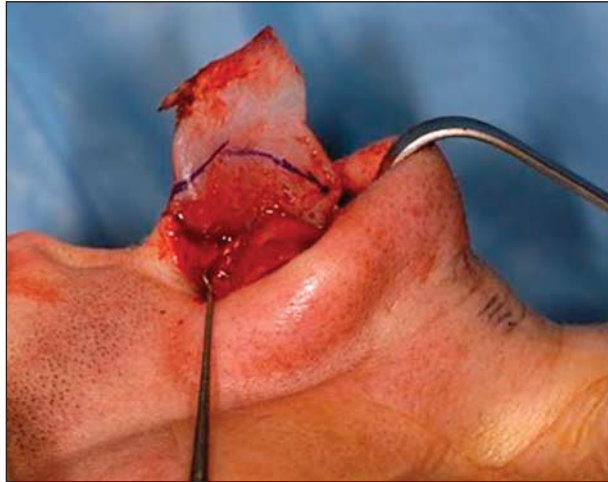With increased understanding of nasal anatomy and its support mechanisms, septal surgery continues to evolve. Conventional endonasal septoplasty continues to be the standard of care for many deviated septa but may not reliably provide an opportunity to correct the more deviated, deformed, C- or cup-shaped septa. For caudal deviations that are cup shaped or deviate off the nasal spine more than 30° in the axial plane, a more aggressive approach is often required to relieve nasal obstruction.

Two previously described techniques for ECS present the surgeon with some technically challenging maneuvers. The original technique by Gubisch<sup>2</sup> used complex maneuvers to resecure the reconstructed septum at the nasal dorsum and caudal nasal spine. Most<sup>3</sup> then simplified Gubisch's technique but still relied on a reconstructed septum of the original cephalocaudal length that had to be fixated to the nasal spine with sutures. This can be a technically challenging and time-consuming surgical step, particularly in revision cases, in which there can be a paucity of nasal spine periosteum, or when the surgeon must bring in special powered instruments to drill a hole in the nasal spine.

We continue to simplify the surgical maneuvers necessary for neoseptum fixation in our technique. This simplification of fixation began with Most,<sup>3</sup> as he simplified the dorsal fixation. Our technique greatly simplifies the fixation in the area of the nasal spine and posterior septal angle. The fabrication of a longer neocaudal septum is a critical step in our technique. By *longer*, we imply a

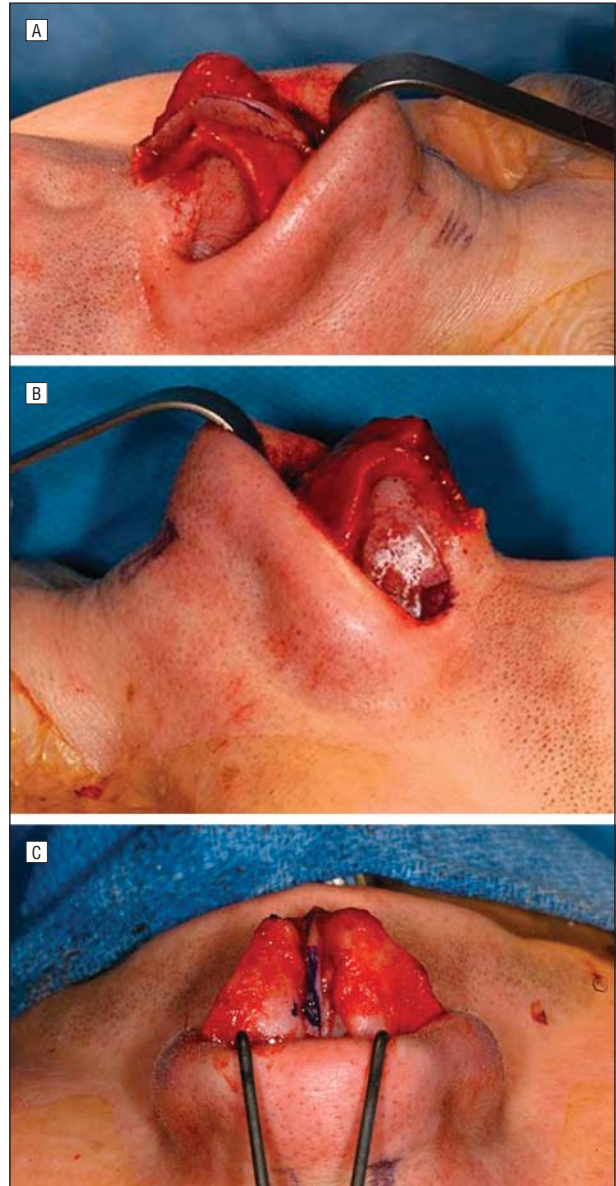


**Figure 5.** Placement of the neocaudal septum back in the nose.



**Figure 6.** Neocaudal septum extending past the caudal border of the medial crura.

septum with a greater cephalocaudal length. Gubisch<sup>2</sup> and Most<sup>3</sup> relied on the creation of a septum of similar length to the native septum, and both of their techniques still required the surgeon to use more technically involved maneuvers to achieve stable midline fixation in the area of the nasal spine. Our technique eliminates this time-consuming part of the procedure and in exchange provides a method of stable midline caudal fixation that is reliable and can be performed much more quickly. After fabrication, the reconstructed neocaudal septum will span the membranous septum and rest at the caudal edge of the medial crura (**Figure 5** and **Figure 6**). This provides several advantages. For one, many patients presenting for complex septal surgery often have concomitant poor tip support. By creating a septum that extends to the medial crura, not only is the airway improved with a midline straightened septum but the medial crural and tip support can be restored as the medial crura are fixated to the neocaudal septum with transcutaneous horizontal mattress sutures (**Figure 7**). This step provides a surgical opportunity to correct traumatic tip ptosis or other tip support maladies. The senior author has developed a simplified technique of fixation of the neocaudal septum to the medial crura. Rather than trying to place buried permanent sutures, he has found that 3 to 4 through-and-through 6-0 polydioxanone sutures are effective. It is important that the entry spot of the 6-0 polydioxanone sutures along the vestibular skin of the



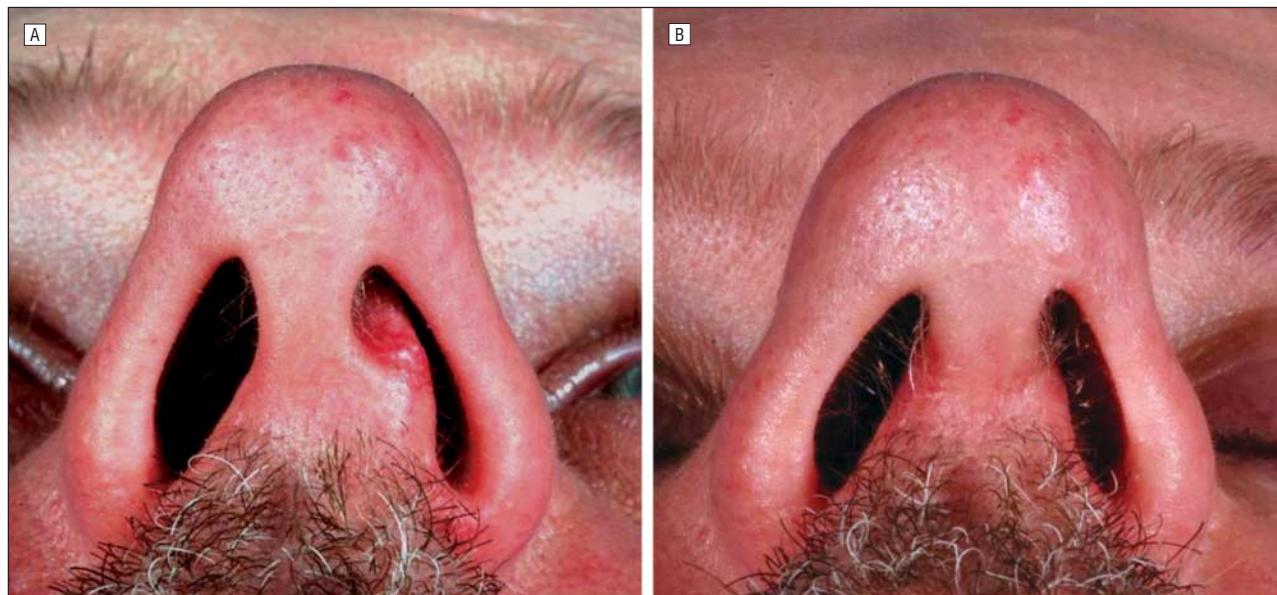
**Figure 7.** Neocaudal septum trimmed to lie flush with the caudal border of the medial crura. A, Lateral view of the neocaudal septum in a very caudal position. B, Lateral view of the neocaudal septum flush with the medial crura. C, Frontal view of the neocaudal septum (marked in blue ink) extending to the caudal border of the medial crura.

medial crura be very close to the exit point of the same suture. That way, only a small amount of medial crura vestibular skin is under the knot. The suture is cut right on the knot. Thus far, no patients have been aware of these transvestibular skin sutures by suture extrusion or by the patient feeling the cut edges of the 6-0 polydioxanone sutures. In summary, much midline stability is achieved with this suture fixation to the medial crura without having to attempt to sew to the nasal spine.

By extending and fixating the neocaudal septum to the medial crura, we effectively stabilize the neocaudal septum. However, we admit that this medial crura fixation alone is not adequate and must be further stabilized with 2 weeks of internal nasal splints.

The senior author has found that cutting the inferior and anterior edges of each splint custom for each case





**Figure 8.** Photographs of a patient before (A) and after (B) undergoing extracorporeal septoplasty with our modified technique.

allows the splints to sit exactly alongside the reconstructed septum. These splints are easy to remove without much pain or bleeding, fit perfectly along the nasal floor, and also fit much more anteriorly along the reconstructed septum, which provides excellent midline stability. Because these splints are sewn in place with through-and-through sutures inferiorly, they tend to pull everything snug into the midline position as the splints pull firmly against the maxillary crest. As through-and-through sutures are placed more caudally, the rigidity of the plastic helps to further stabilize the reconstructed neocaudal septum exactly where it is fixated in the midline between the medial crural cartilages (Figure 4). The senior author also routinely places patties of crushed cartilage near the nasal spine under the assumption that these add further fibrotic midline adhesion. The sum of all of these maneuvers helps to decrease surgical time and makes the surgery less technically challenging and less time-consuming (**Figure 8**). We believe that, as the technique of ECS continues to evolve and simplify, more nasal surgeons will embrace this new surgical method with which they can more reliably correct some of the most challenging septal deformities.

## CONCLUSIONS

The use of ECS for the correction of the severely deviated caudal septum is a relatively new technique. Little is still known about the complication rates associated with this technique; however, current data indicate the rates to be comparable to those of standard endonasal septoplasty, making this a safe procedure to perform.

Our technique for fixation of the anterior portion of the neocaudal septum replaces the need for suturing to wispy (or nonexistent) periosteum or for drilling a hole into the nasal spine. Anterior fixation is accomplished by simply extending the neocaudal septum to the medial crura and using familiar through-and-through mat-

ress sutures to secure the neocaudal septum. Further stabilization is accomplished with intranasal splints.

**Accepted for Publication:** November 2, 2010.

**Correspondence:** Matt A. Wilson, MD, Division of Otolaryngology–Head and Neck Surgery, University of Utah School of Medicine, 50 N Medical Dr, Room 3C120, Salt Lake City, UT 84132 (matthew.wilson@hsc.utah.edu).

**Author Contributions:** *Study concept and design:* Mobley. *Acquisition of data:* Wilson and Mobley. *Analysis and interpretation of data:* Wilson and Mobley. *Drafting of the manuscript for important intellectual content:* Wilson and Mobley. *Statistical analysis:* Wilson and Mobley. *Study supervision:* Mobley.

**Financial Disclosure:** None reported.

**Previous Presentation:** This study was presented at the 10th Annual International Symposium of Facial Plastic Surgery, American Association of Facial Plastic and Reconstructive Surgery; May 2, 2010; Hollywood, Florida.

## REFERENCES

1. Wright WK. Principles of nasal septum reconstruction. *Trans Am Acad Ophthalmol Otolaryngol.* 1969;73(2):252-255.
2. Gubisch W. The extracorporeal septum plasty: a technique to correct difficult nasal deformities. *Plast Reconstr Surg.* 1995;95(4):672-682.
3. Most SP. Anterior septal reconstruction: outcomes after a modified extracorporeal septoplasty technique. *Arch Facial Plast Surg.* 2006;8(3):202-207.
4. King ED, Ashley FL. The correction of the internally and externally deviated nose. *Plast Reconstr Surg (1946).* 1952;10(2):116-120.
5. Gubisch W, Constantinescu MA. Refinements in extracorporeal septoplasty. *Plast Reconstr Surg.* 1999;104(4):1131-1142.
6. Gubisch W. Extracorporeal septoplasty for the markedly deviated septum. *Arch Facial Plast Surg.* 2005;7(4):218-226.
7. D'Andrea F, Brongo S, Rubino C. Extracorporeal septoplasty with paramarginal incision. *Scand J Plast Reconstr Surg Hand Surg.* 2001;35(3):293-296.
8. Senyuva C, Yücel A, Aydin Y, Okur I, Güzel Z. Extracorporeal septoplasty combined with open rhinoplasty. *Aesthetic Plast Surg.* 1997;21(4):233-239.
9. Bloom JD, Kaplan SE, Bleier BS, Goldstein SA. Septoplasty complications: avoidance and management. *Otolaryngol Clin North Am.* 2009;42(3):463-481.