

Extracorporeal Septoplasty: Assessing Functional Outcomes Using the Validated Nasal Obstruction Symptom Evaluation Score over a 3-Year Period

Steven Ross Mobley, M.D.
Jennifer Long, M.D.

Salt Lake City, Utah

Background: It is well recognized that the standard septoplasty approach, in patients with severe septal deformities, may be less than adequate to address all portions of the deviated septum. The extracorporeal septoplasty technique is an alternative to the other common approaches in these more severe cases. In this study, the authors investigate functional outcomes of the standard approach. The authors use the validated Nasal Obstruction Symptom Evaluation score, before and after surgery, to quantify symptom improvement and confirm the validity and usefulness of this method in treating severe septal deviation.

Methods: A retrospective collection of clinical data was performed on all patients undergoing extracorporeal septoplasty in a 28-month period from January of 2010 through May of 2013. Fifty-five patients were identified. Demographic information, previous surgical history, and complication status were collected. The main outcome measured was functional outcome identified from preoperative and postoperative Nasal Obstruction Symptom Evaluation scores. Collaboration occurred with the study design and biostatistics center for statistical analysis.

Results: The median preoperative and postoperative Nasal Obstruction Symptom Evaluation scores were 14.5 (interquartile range, 11.0 to 16.0) and 3.0 (interquartile range, 1.0 to 5.0), respectively. The median change between preoperative and postoperative scores was a decrease of 9.0 (interquartile range, 25.0 to 47.5). It was a statistically significant difference with ($p < 0.0001$) (Wilcoxon signed rank test).

Conclusions: Extracorporeal septoplasty is an important surgical option for repair of the severely deviated nasal septum. This study shows significant improvements in functional outcomes following this procedure, as shown by notable improvements in the validated Nasal Obstruction Symptom Evaluation score after extracorporeal septoplasty surgery. (*Plast. Reconstr. Surg.* 137: 151e, 2016.)

CLINICAL QUESTION/LEVEL OF EVIDENCE: Therapeutic, IV.



The relationship between subjective nasal obstructive symptoms and anatomical features of the nasal septum is well known, with septal deviation being one of the most common findings in patients with symptomatic nasal obstruction. Septoplasty has become established

as one of the most frequently performed surgical procedures in the otolaryngological field. Septoplasty provides an effective treatment for symptomatic septal deformity in the majority of cases. Traditional septoplasty can be used to adequately manage a majority of septal deformities, with favorable improvements in nasal function and sometimes aesthetics.

From Mobley MD Facial Plastic & Reconstructive Surgery, PLLC.

Received for publication May 22, 2014; accepted August 24, 2015.

Copyright © 2015 by the American Society of Plastic Surgeons

DOI: 10.1097/PRS.0000000000001885

Disclosure: The authors have no financial interest to declare in relation to the content of this article.

However, there is significant variation in the anatomy and complexity of septal deviation. Numerous classification systems have been proposed to serve as an aid in the assessment of such patients. These systems, some of which include up to seven grades of septal deviation, are intended to assist the surgeon in preoperative analysis and surgical planning. In general, the most complex septal deviations are characterized by massive malformation at all levels of the septum, often with a C-shaped cup of caudal septum, and consecutive obstruction of one or both nostrils. Many authors deem the classic septoplasty approach unsuitable in these severe cases, as it is unable to provide an adequate improvement in functional and aesthetic outcomes, and is prone to recurrence of septal deformity.

Extracorporeal septoplasty has been proposed as a more suitable technique for the severely deviated nasal septum. King and Ashley first proposed extracorporeal septoplasty in the 1950s. It was introduced with the intention of curing the most severe septal deviations, or to restore the loss of septal portions. In this procedure, the quadrangular cartilage is removed and a neoseptum is constructed using one of a number of surgical techniques. These techniques include fabrication of a neoseptum using the native septal cartilage, costal or auricular cartilage, or (in more recent literature) these cartilage sources in combination with a polydioxanone plate. Following reconstruction, the neoseptum is reimplanted between the two mucoperichondrial flaps, and the cartilaginous nasal dorsum is reconstructed.

Extensive work has subsequently been performed over the past 30 years, refining the extracorporeal septoplasty technique and recommending it as a safe and successful alternative surgical option for the correction of a considerably deviated septum.^{1,2} In particular, Gubisch³ has performed and published large studies on the extracorporeal septoplasty technique, documenting well the validity of this procedure and its suitability for use by the surgeon.^{4,5} Despite this, the literature is still somewhat lacking in data confirming any improvement in patient symptoms following the standard extracorporeal septoplasty procedure. In response to this, our study aims to quantify how effective the standard extracorporeal septoplasty technique is by performing the procedure in conjunction with patient-reported outcomes. We use the validated Nasal Obstruction Symptom Evaluation scale,

both preoperatively and postoperatively, as a measure of this.

The Nasal Obstruction Symptom Evaluation scale was developed to document whether septoplasty is effective in improving symptoms of nasal obstruction. A multicenter prospective instrument validation study was performed with 32 adults with nasal septal deformity. The final instrument test-retest reliability was found to be adequate at 0.702; internal consistency reliability was also adequate at 0.785. Reliability was assessed using the Goodman-Kruskal coefficient; a value of at least 0.70 was considered adequate test-retest reliability. Validity was confirmed using correlation and comparison analysis, and response sensitivity was excellent. The final instrument consists of five questions multiplying the raw score by 5 to get a total score between 0 and 100. A score of 0 correlates with no problems associated with nasal obstruction, and a score of 100 means the worst possible problems with nasal obstruction.⁶ Although the Nasal Obstruction Symptom Evaluation scale used in this study is an effective measurement with which to assess nasal obstruction by means of patient symptomatology, clearly there are other methods such as rhinomanometry that can also be used to further objectively assess functional nasal obstruction.

We will briefly discuss reimbursement payments comparing the standard septoplasty and extracorporeal septoplasty techniques to expand on the facts that extracorporeal septoplasty takes significant amounts of surgical time and is a complex procedure. Furthermore, in selected cases, it is a strongly indicated procedure for completely repairing the most complex septal deformities. We thereby aim to secure the extracorporeal septoplasty as an important and valuable surgical option for the otolaryngologist when it is deemed that traditional septoplasty may not be optimal when surgically managing the most severely deviated nasal septa.

PATIENTS AND METHODS

Permission from the institutional review board was obtained by the University of Utah Review Committee. A retrospective review of patient charts was performed on all patients who had undergone extracorporeal septoplasty from January of 2010 through May of 2013. A single surgeon who operates in a multistate referral practice performed all procedures. A strict patient selection process was used.

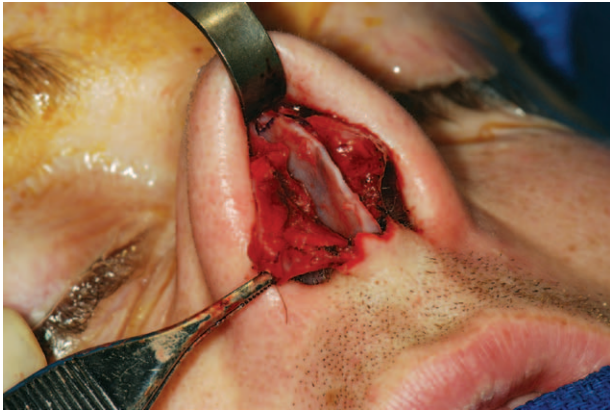


Fig. 1. Photograph demonstrating that in this extracorporeal septoplasty technique, the neo-caudal septum spans the membranous septum, extending to the caudal border of the medial crura.

Patients selected for the extracorporeal septoplasty technique had a C- or cup-shaped septum and/or a septum that had come off the nasal spine at an angle greater than 30 degrees in the axial plane. In this series, a majority of patients had already undergone a traditional septoplasty but were left with persistent nasal obstruction. The extracorporeal septoplasty technique was then used to further correct deformities not completely corrected by the original septoplasty and carried with it a very high functional outcome success.

The severely deviated septum possesses an elastic “memory,” which can make correction of the septum a larger surgical challenge. Traditional techniques used to treat the severely

deviated septum, such as scoring, do not completely address the bend that can be inherent in the severely deviated septum and as such the septum will frequently regress to the original position because of cartilaginous “memory.” Extensive research, particularly by Gubisch, has shown extracorporeal septoplasty to be an effective technique in treating the severely deviated septum, as extracorporeal septoplasty serves to replace the severely bent septum with straight cartilage rather than trying to weaken the bent cartilage in hopes that it will not rebend in the postoperative period.⁷ Extracorporeal septoplasty offers the surgeon the ability to correct the septum under direct visualization, replacing deformed cartilage with strong, straight, non-weakened cartilage, and providing both form and function for the patient with a high-complexity septal deviation (Fig. 1).

We begin the operation with a standard inverted-V transcolumellar incision connecting to the internal medial marginal incisions to deglove the nose; this is the same incision we use for any standard functional or cosmetic external approach for septorhinoplasties. Then, we split the medial crura using monopolar cautery on the cut setting. We then encounter the caudal edge of the septum. Because this is for an extracorporeal technique, the septum is usually significantly off midline, and it is important to perform this dissection between the medial crura carefully so as to not buttonhole through the flaps.

Once the anterior edge of the caudal septum is identified, sharp dissection with a no. 15c blade

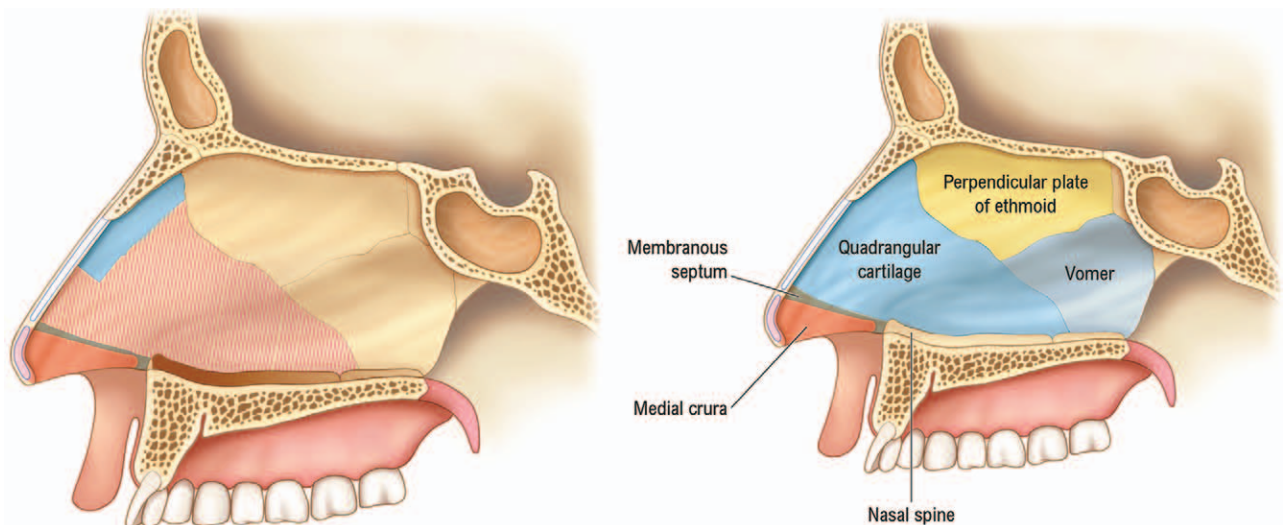


Fig. 2. (Left) Medical illustration of nasal/septal anatomy. Red lines represent the amount of quadrangular cartilage removed in the extracorporeal septoplasty technique. Light blue represents the amount of 1-cm dorsal native cartilage that is not removed and is later sewn to, when replacing the neo-caudal septum. (Right) Anatomy.

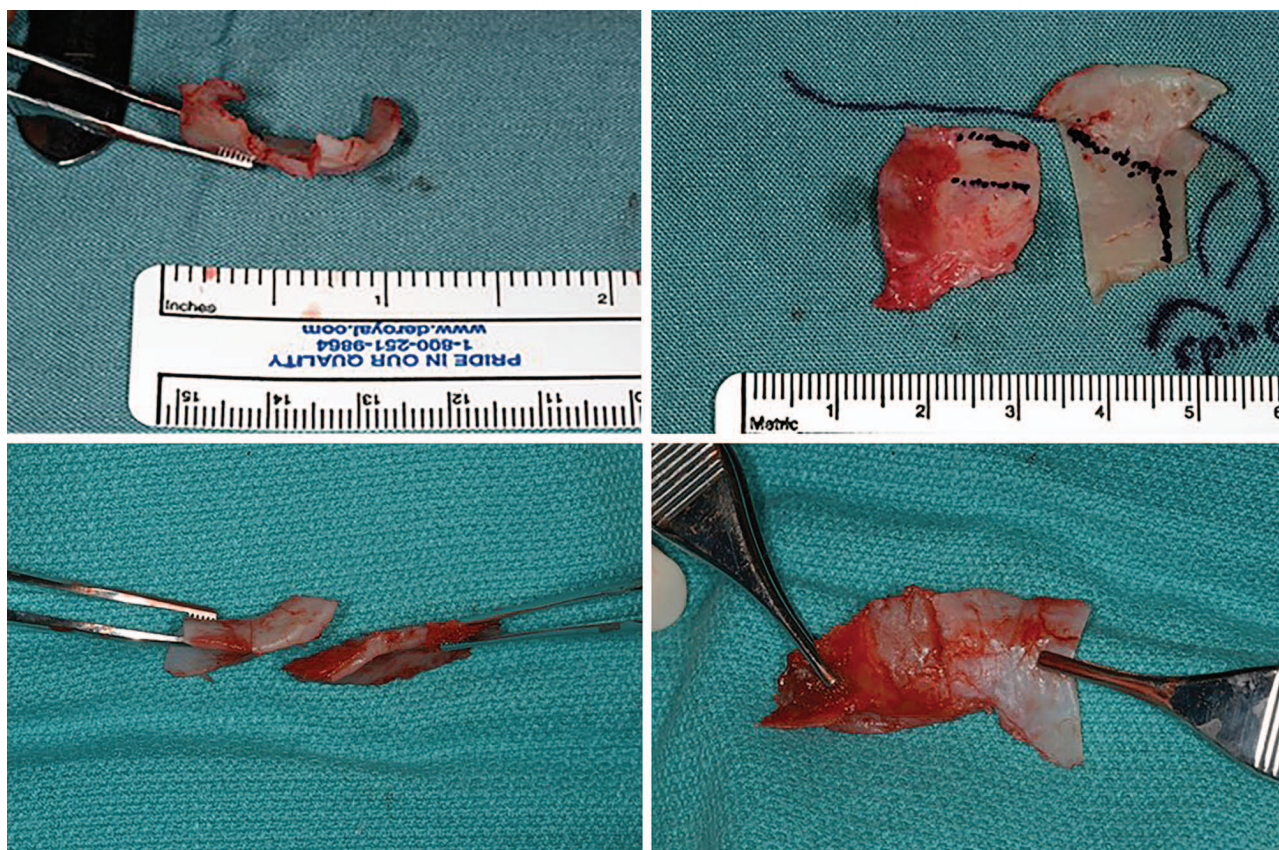

Fig. 3. (Above, left) Classic extracorporeal septoplasty septum that is quite crooked and removed in total. (Above, right) The surgeon has cut the original septum into its smaller flatter pieces and begins to determine how they will be fabricated into a neoseptum. (Below) An example of how two pieces with slight bends to them can be overlapped and sewn back together to form a straight neoseptum.

is used to gain entrance to the submucoperichondrial plane; then, standard Freer elevation is used to raise mucoperichondrial flaps. Because an extracorporeal septoplasty technique is being used, it is not uncommon that there has been previous septal

surgery and/or trauma and that the dissection and raising of the perichondrial flaps is generally slow going, as there are frequently significant twists, turns, and previous septal fractures, all of which can make raising the septal flaps without any tears when working around them challenging.

Once the wide dissection of septal flaps has been performed posterior to the bony cartilaginous junction to the nasal septum, the Beaver 6900 blade (Beaver-Visitec International, Inc., Waltham, Mass.) is brought in and a 1-cm dorsal strut is left behind as a through-and-through cartilaginous incision is made with a Beaver 6900 blade and then brought forward toward the anterior septal angle. Some of the dorsal septum off to the dorsal 1-cm caudal portion of the septum will also be incised with the Beaver 6900 blade maneuver. The septum is freed from the bony cartilaginous junction with a Freer elevator and is freed from the floor with either a Freer elevator dissection or sharp dissection with a Beaver 6900 blade. The goal is to excise the

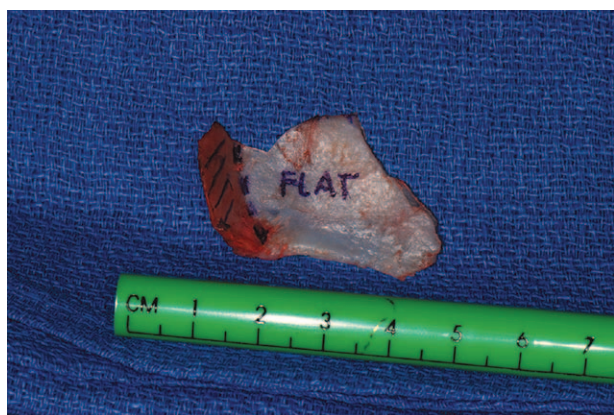

Fig. 4. Intraoperative view shows a relatively flat piece of septum posterior to a quite crooked anterior septal deflection (blue diagonal lines).

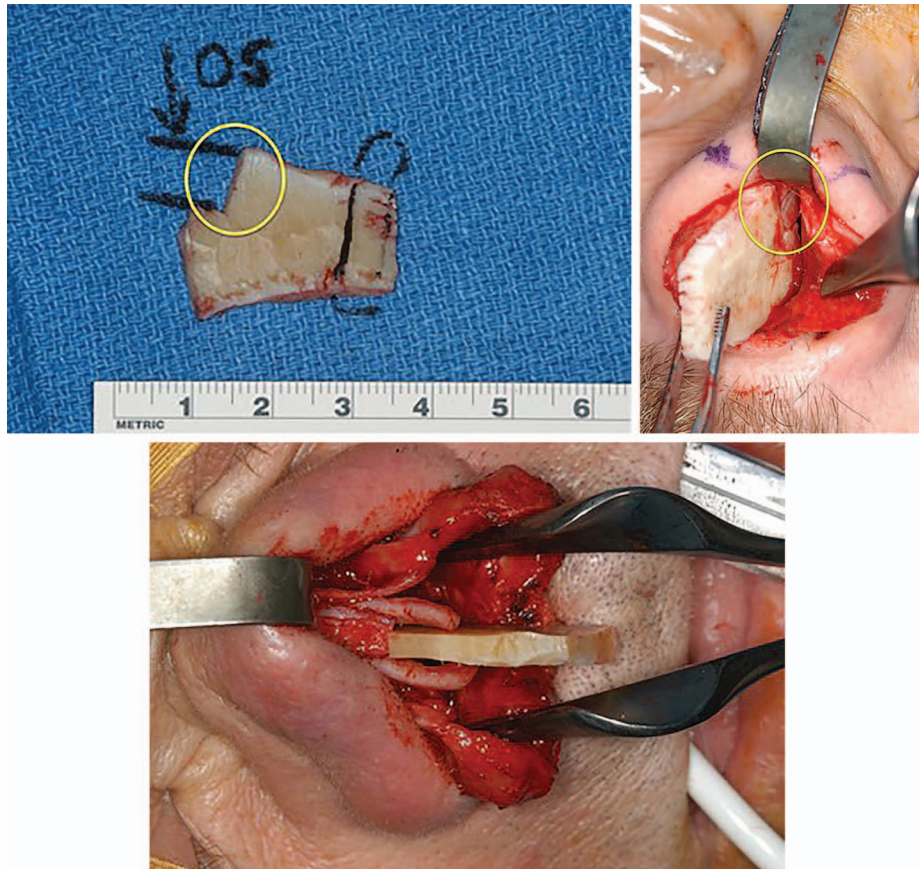


Fig. 5. (Above, left) Example of how the original dorsal septum (OS) will fit like a puzzle piece to the carved flat piece of rib acting as a neoseptum. (Above, right) Actual intraoperative view of the rib neoseptum placed precisely in conjunction with the original dorsal septum. (Below) Extended spreader grafts are then placed alongside the rib to help further stabilize it in the midline.

entire septum, although it is usually tortuously deviated in several different directions, in one piece (Fig. 2).

The septum is then brought onto the back table and examined. The surgeon will usually appreciate that, although the overall septum has many twists and bends to it (Fig. 3), there are certain sections of the overall twisted septum that are flat. The surgeon can cut along the areas of maximum deflection and often finds that there are flat pieces “within” the very crooked septum (Fig. 3, above). These flat sections then often become two or three smaller working pieces. These small- to medium-size pieces are then fashioned back together to form a neo-caudal septum (Fig. 3, below). Although there is no exact sequence that can direct this, the surgeon will need flexibility in intraoperative judgment to achieve a straightened neoseptum. Sometimes, simply “flipping” the septum around helps create a straighter septum. For example,

the posterior portion of the septum may be relatively straight (Fig. 4). Because the septum has been explanted, the posterior septum can be rotated 90 degrees and brought anteriorly to form the new anterior neo-caudal septum. In this situation, the crooked anterior areas of septum are simply excised, crushed, and placed back between the flaps. In other situations, especially in revisions when the prior surgeon removed a good deal of quadrangular cartilage, auricular cartilage or rib may be brought in. When rib is used, it can often be trimmed and thinned down to become the neo-caudal septum (Fig. 5). A polydioxanone plate can also be helpful when reassembling several smaller pieces of cartilage back into an appropriate sized neo-caudal septum (Fig. 6). Especially when ear cartilage is used, the polydioxanone plate will provide a flat scaffolding on which to affix the auricular cartilage and thus help to straighten the auricular cartilage. Whichever techniques are used,

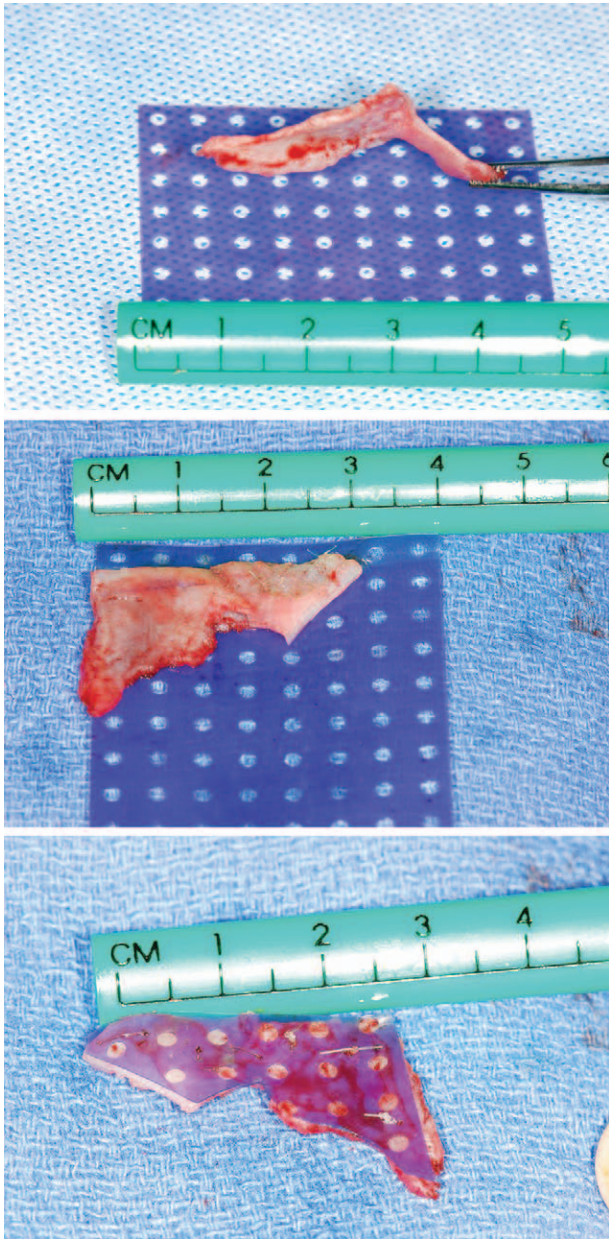


Fig. 6. An explanted tortuously deviated septum placed alongside a polydioxanone plate before the surgeon has cut the native septum into smaller workable pieces. The small to medium-size pieces of native septum are all now sewn to the polydioxanone plate, which provides an excellent straight, flat scaffold on which to fabricate a neoseptum.

the final result is that the surgeon produces a straight L-shaped configuration to make a strong and straight neoseptum that will have enough of an anterior septal angle and dorsal extension to be sewn back to the native dorsal remnant that was not excised when the septum was explanted. As most of these noses have slight deviation in the middle vault, the dorsal remnant is studied

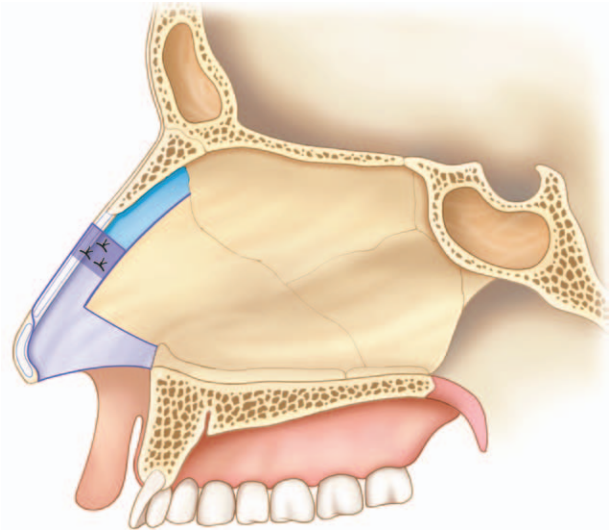


Fig. 7. Medical illustration showing how the fabricated neoseptum (*purple-blue*) overlaps the native dorsal remnant not removed (*sky blue*) and the three 5-0 nylon sutures used to laminate these pieces together.

and, for example, if the dorsal septal remnant deviates slightly off to the patient’s left side, the neoseptum will be placed between the right upper lateral cartilage and the right side of the dorsal remnant. The dorsal remnant and the neoseptum are now sewn together with through-and-through 5-0 nylon sutures, and three to five key through-and-through suture fixations to fixate the dorsal septum (Fig. 7). The neoseptum should span the membranous septum, so that the caudal edge of the neoseptum is flush caudally with the caudal edges of the medial crura. A 6-0 polydioxanone suture is then used to go through and through from the vestibular skin of the medial crura, through the neo-caudal septum (which is now positioned between the medial crura), the needle exits the opposite side, and then the needle is brought back through again. Through-and-through 6-0 polydioxanone suture horizontal mattress sutures are placed to stabilize the septum in the midline.

In Figure 6, the use of the polydioxanone plate is shown. However, only four patients in this series had polydioxanone plating used as part of their reconstruction. When a polydioxanone plate is used, it basically is used as stable “platform” on which to sew smaller pieces of cartilage. As more pieces are sewn to the polydioxanone plate, they begin to collectively function as one larger piece of straight cartilage.

In most cases, the tip is then reapproximated to avoid having any changes on tip position or

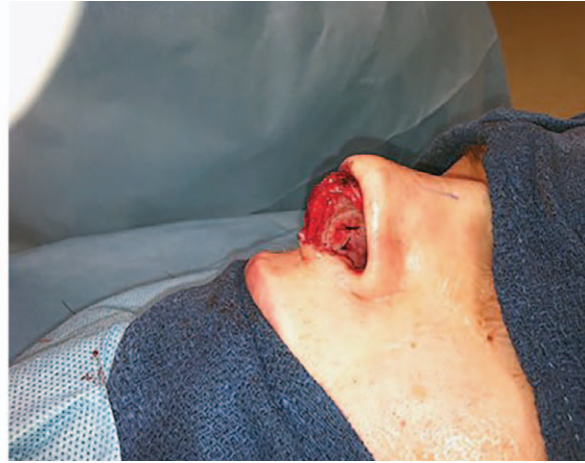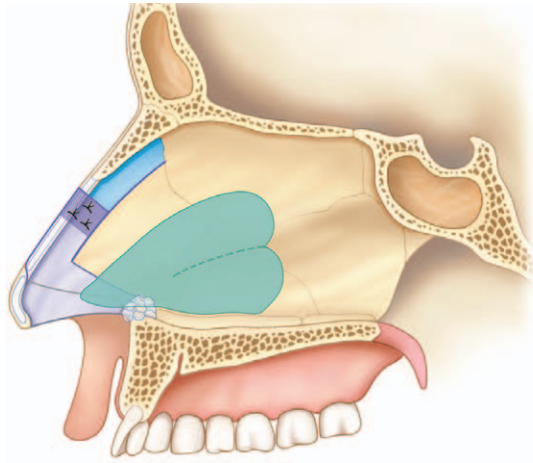


Fig. 8. (Left) Medical illustration that demonstrates how inferiorly and caudally the custom cut splints are positioned. Notice the patty of crushed cartilage near the nasal spine, which assists in the “bricks-and-mortar” reconstruction principles. (Right) Actual intraoperative photograph demonstrates how caudal and inferior the splints are positioned internally.

rotation. In certain cases where severe anterior septal deformity has led to a loss of tip support and tip ptosis, the medial crura can be positioned along the neo-caudal septum using a tongue-and-groove technique to rotate the tip position upward. Subsequently, custom-cut splints are then placed on either side of the septum (Fig. 8). The splints should sit low along the nasal floor but then also come rather caudally anterior so that they rest just adjacent to the medial crura. Then, through-and-through 4-0 black nylon sutures are used to suture fixate the splints in place. As the knots are tied across the splints, the splints naturally snug things into the midline, which further adds a significant amount of midline neoseptum stabilization (Fig. 9).

The University’s patient coding system was used to identify patients who underwent

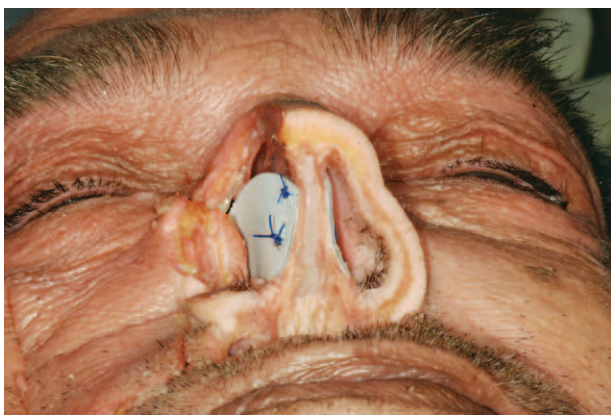


Fig. 9. Cadaver photograph demonstrates how, as the through-and-through sutures of the splints are tightened, the septum is “snugged” to the midline.

extracorporeal septoplasty within our set time frame. An additional manual search through the surgery scheduler’s diary identified a further nine patients who had been erroneously omitted from the coding search.

Data reviewed included age, sex, previous surgery, details of the procedure including material used, and complications. During their initial clinic visit, patients were given a preoperative Nasal Obstruction Symptom Evaluation questionnaire to complete. This was performed to objectively track and measure postoperative outcomes, but Nasal Obstruction Symptom Evaluation scores were not specifically used to determine who did or who did not undergo extracorporeal septoplasty. Other testing (i.e., functional testing such as rhinomanometry) was not performed simply because this particular equipment was not available at the University at the time of this study. A subsequent postoperative Nasal Obstruction Symptom Evaluation questionnaire was given to the patients, typically in the postoperative visit between 3 and 6 months after surgery. We collaborated with the study design and biostatistics center for statistical analysis of these results.

RESULTS

In total, 55 subjects underwent the extracorporeal septoplasty procedure in the 29-month period. The senior surgeon has a busy functional nasal surgery practice, but only top-tier complex septal deformities are selected for the extracorporeal septoplasty technique. Of those subjects,

Table 1. Descriptive Statistics

Characteristic	Value (%)
Mean age \pm SD, yr*	36.02 \pm 15.20
Sex	
Male	35 (63.6)
Female	20 (36.4)
NOSE score	
Preoperative	
Median	14.5
IQR	11.0–16.0
Postoperative	
Median	3.0
IQR	1.0–5.0
Change between postoperative and preoperative	
Median	-9.0
IQR	25.0–47.5

NOSE, Nasal Obstruction Symptom Evaluation; IQR, interquartile range.

*There were a total of 55 subjects, and three were missing age information.

63 percent ($n = 35$) were male. The average age of the subjects was 36.0 ± 15.2 years. Median follow-up time was 2 months (8 to 9 weeks) postoperatively.

The median preoperative and postoperative Nasal Obstruction Symptom Evaluation scores were 14.5 (interquartile range, 11.0 to 16.0) and 3.0 (interquartile range, 1.0 to 5.0), respectively. The median change between preoperative and postoperative Nasal Obstruction Symptom Evaluation score was decreased approximately 9.0 (interquartile range, 25.0 to 47.5). This shows a statistically significant difference of $p < 0.0001$ (Wilcoxon signed rank test) between preoperative and postoperative Nasal Obstruction Symptom Evaluation scores.

Descriptive statistics were reported using frequency and percentage for categorical data, mean \pm SD for normally distributed numerical data, and median (interquartile range) for

nonnormally distributed numerical data. The paired nonparametric method Wilcoxon signed rank test was used to examine the change between preoperative and postoperative Nasal Obstruction Symptom Evaluation scores. A value of $p < 0.05$ was set to determine statistically significant differences. All of the analyses was performed using SAS 9.2 (SAS Institute, Inc., Cary, N.C.) (Table 1 and Fig. 10).

In the postoperative period, observations were also made to the external appearance of the nose. No saddles were seen, and the main change in external appearance was more symmetrical nostrils seen on basal view (Figs. 11 through 13). We have seen no settling of the nasal dorsum, and this would not be anticipated, because a guiding principle of extracorporeal septoplasty technique is to leave the nose, septum, and bridge stronger (and straighter) than they were preoperatively. Other factors contribute to this strength concept: for example, the technique adheres to the time-tested principle of leaving at least 1 cm of dorsal strut. Once the neoseptum is fabricated, it is sewn to the 1-cm dorsal remnant with several through-and-through 5-0 nylon sutures. The neoseptum overlaps the native dorsal septal remnant by at least 6 mm (with 6 to 10 mm of overlap being ideal (Fig. 8)). This allows for at least three through-and-through 5-0 nylon sutures to “baste” the neoseptum to the dorsal 1-cm remnant, thus creating a firm and stable dorsal septum that does not settle or saddle with time.

Polydioxanone plates were used in just four patients. In this subset of four patients, we did not see any increase in complications, nor did we see any long-term problems with the stability of the reconstructed neoseptum. The senior

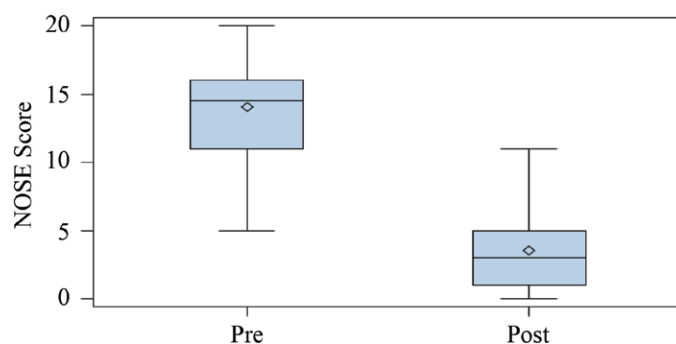


Fig. 10. Distribution of preoperative and postoperative Nasal Obstruction Symptom Evaluation (NOSE) score. The order of the statistics shown in this box-and-whisker plot is maximum, 75th quartile, median or mean, 25th quartile, and minimum value.

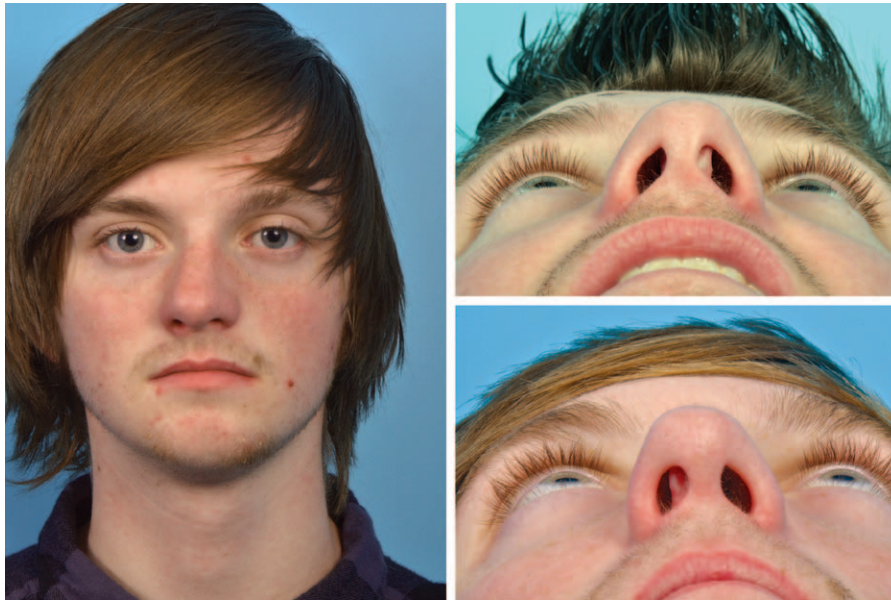

Fig. 11. An example of twin brothers preoperatively and postoperatively, showing more symmetrical nostrils after extracorporeal septoplasty surgery. Before, frontal and base views are shown.

author (S.M.) has used both the 0.25- and 0.15-mm polydioxanone plates and has anecdotally observed less postoperative septal edema with the 0.15-mm thickness. However, to add clarity, the purpose of this study was to focus on the functional outcome of extracorporeal septoplasty technique, and because polydioxanone plates were used in only a small portion of cases, extra data related

specifically to polydioxanone plate use were not compiled.

DISCUSSION

All patients who underwent the extracorporeal septoplasty procedure in our study were selected based on having top-tier deviated septa

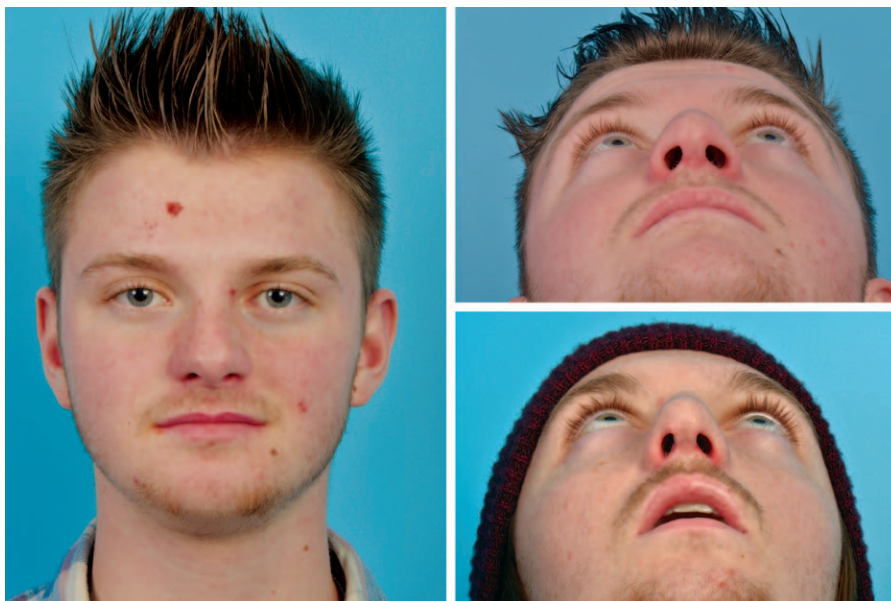

Fig. 12. An example of twin brothers preoperatively and postoperatively, showing more symmetrical nostrils after extracorporeal septoplasty surgery. After, frontal and base views are displayed.



Fig. 13. Frontal views of the twin brothers shown in Figs. 11 and 12.

(e.g., anteriorly “cup-shaped” septa involving the caudal 1 cm of septal cartilage, deviated septa where the septum is twisted and protruding out of the nostril, and deviated septa where the septum is so much off midline that it is in direct contact with the internal lateral nasal sidewall) (Fig. 6). This study shows that the standard extracorporeal septoplasty procedure significantly improves nasal obstructive symptoms in patients with the most severe of nasal septal deviations, many of whom would not potentially receive such maximum benefits from traditional septoplasty. The tool used to determine the severity of nasal obstructive symptoms, the Nasal Obstruction Symptom Evaluation system, is a validated and reliable tool for measuring outcomes in adults with nasal obstruction. The median change from preoperative to postoperative Nasal Obstruction Symptom Evaluation scores was -9.0 . This improvement in Nasal Obstruction Symptom Evaluation score directly reflects how significantly this procedure can improve symptoms and (nasal) quality of life.

Although there is a large amount of evidence in the current literature recommending extracorporeal septoplasty as a safe and successful option for the markedly deviated nasal septum, this is one of the first studies that uses a validated scoring system to quantify the functional outcomes following extracorporeal septoplasty. Our study shows that patients with the most severe septal deviations can have a significant functional benefit from

extracorporeal septoplasty. This improvement in symptoms is shown to be statistically significant.

The main purpose of this article is to add to the body of peer-reviewed literature regarding the proven functional outcomes following extracorporeal septoplasty surgery. This study did not attempt to quantitatively measure aesthetic outcomes per se. That stated, it is true that many patients with severe septal deviations and irregularities also have crooked appearing noses. Sometimes, these patients' noses appear crooked on frontal view and others appear relatively straight on frontal view but have quite asymmetrical basal views. Patients whose noses appear crooked on

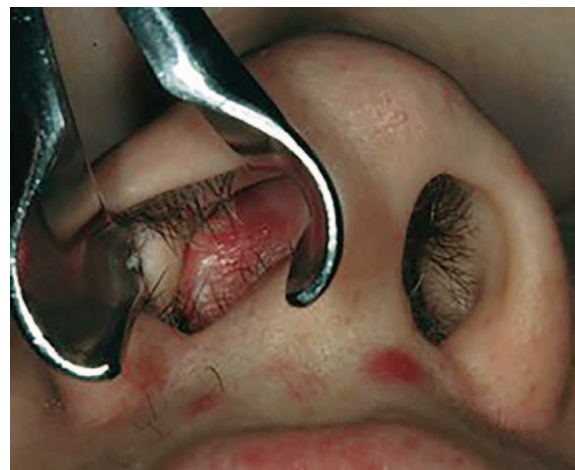

Fig. 14. Severe caudal septal deviation spanning from the midline to the internal lateral nasal sidewall resulting in complete anatomical obstruction of the right naris.

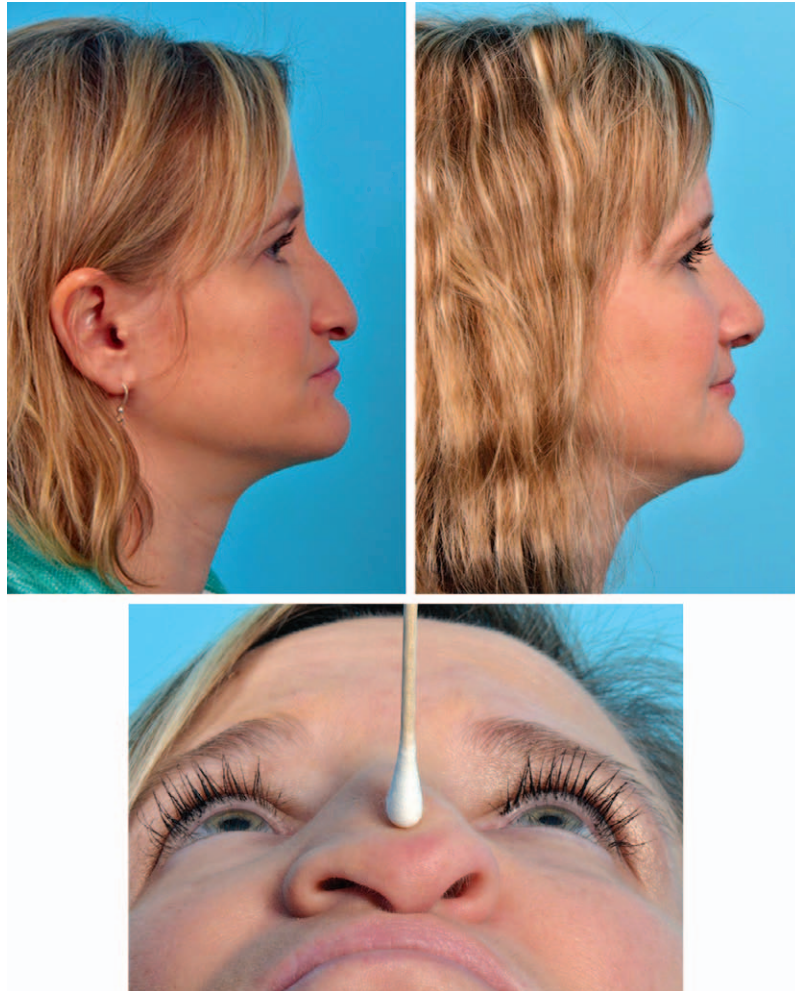


Fig. 15. Example of how the extracorporeal septoplasty technique can provide a strong neo-caudal septum that can be used to address functional (or cosmetic) tip ptosis by using classic tongue-in-groove technique to pexy the medial crura onto the neo-caudal septum, resulting in reliable, long-lasting tip ptosis correction.

frontal view and who are under the care of the senior author and who are undergoing purely functional septal surgery are often told that undergoing extracorporeal septoplasty surgery will help the crooked nose appear straighter. However, the emphasis is placed on the word “straighter,” not “straight.” Although several of the patients whose noses appeared crooked on frontal view appeared straighter after undergoing extracorporeal septoplasty technique, these types of aesthetic data were not routinely collected, as they were not part of our original study design to quantify the aesthetic outcome of “straightness.”

The cases presented in this article are of extreme anterior septal deviations. When the anterior septum is mildly to moderately off center, it will have only a minimal effect on nasal breathing,

as air can still get around these mild to moderate deviations in the anterior nares. However, patients in this series have severe anterior septal deviations. It is not uncommon for the septum to be 30 to 60 degrees off of the midline in the sagittal plane. As such, these patients often have the anterior septal deviation actually touching the inside of the internal lateral nasal sidewall, often causing a complete anterior anatomical blockage (Fig. 14).

When the technique is performed as described in this article, the anterior nose is not destabilized. It could be contemplated that there is a risk of destabilizing the nose using our extracorporeal septoplasty technique because most of the septum is (temporarily) removed and then reimplemented. To the contrary, the entire septum,

and particularly the caudal “neoseptum,” is actually more stable after this technique is performed. We have seen no cases of postoperative “slipping” of the septum out of the midline of the nose. It is the senior author’s (S.M.) belief after over 10 years of using his novel splinting technique that the reconstructed nose/septum is actually more stable than the native nose before surgery. There are several reasons for this.

First, we always leave a minimum of 10 to 12 mm of dorsal septum in the nose when we explant the septum. This leaves plenty of stable dorsal septum to which we sew the midbody of our neoseptum with multiple through-and-through 5-0 nylon sutures.

A second important factor that increases septum stability is the fact that patients with severe caudal septal deviations often have a lack of continuity between the supporting ligaments of the caudal septum and the medial crura. As a result, patients that need extracorporeal septoplasty often present with tip ptosis (Fig. 15). During the extracorporeal septoplasty procedure, using the techniques described in this article, the caudal edge of the “neoseptum” is placed between the medial crura (Figs. 11 through 14). Because the neoseptum is “sandwiched” between the medial crura, the medial crura themselves provide further midline stabilization of the neoseptum, acting as lateral stabilizers to help hold everything in the midline.

Furthermore, our use of small patties of crushed cartilage (Fig. 8) allows for a bricks-and-mortar type healing process, wherein the new septum and the medial crural cartilages act as the “bricks” and the smaller patties of crushed cartilage act as the “mortar.” Furthermore, the use of custom-cut nonperforated plastic splints allow everything to be “cinched” into the midline and further adds a tremendous amount of stability to the newly reconstructed midline septum. The splints are routinely left in for 2 weeks. The senior author has not experimented with removing the splints earlier; however, 2 weeks has worked well for over a decade of patient care.

We believe that this study adds a great deal to the current literature with regard to the most effective way in which to manage severe nasal septal deviations, and also shares our own modifications of the extracorporeal septoplasty technique. After a careful search of the PubMed database using dates within the range of 1990 to 2014, to our knowledge, this is one of the first to use the Nasal Obstruction Symptom Evaluation score as a functional outcome to quantify improvements

in symptoms. Authors such as Gubisch, Most, and a previous article by Mobley have traditionally focused on surgical methods.

In almost all cases of extracorporeal septoplasty, there is a need for increased operating room time and a corresponding increase in surgical complexity. A brief financial analysis of a mix of third-party payers demonstrated an average reimbursement of extracorporeal septoplasty three or four times that of traditional septoplasty. This is appropriate when considering that a “routine” extracorporeal septoplasty surgical case may take three or four times as long to perform compared with traditional septoplasty, and is easily three- or fourfold more surgically complex. The authors are not advocating that a majority of deviated septa be treated by extracorporeal septoplasty, but do acknowledge that for top-tier nasal septal deviations, especially those that have failed traditional septoplasty in the past, extracorporeal septoplasty is a safe and effective technique with a now validated questionnaire-proven efficacy for improving functional nasal outcomes.

We believe this study fully addresses our goal of quantifying symptom improvement following extracorporeal septoplasty, and confirms the validity of this procedure in treating the patient with severe septal deviation. Although these results are statistically significant, we believe that further work would benefit from a larger sample size. A single surgeon performed all surgical work; further studies could pool outcomes from a number of surgeons in different surgical centers to reduce any operator-dependent outcomes. Work in the future may be able to address this and measure outcomes, for example, at 10 years postoperatively, to confirm a reliable and sustained improvement in symptoms.

Steven Ross Mobley, M.D.
5292 South College Drive
Salt Lake City, Utah 84123
mobley@mobleymd.com

ACKNOWLEDGMENT

The authors acknowledge Brad Boren for significant administrative efforts in the preparation and submission of this article.

PATIENT CONSENT

Patients, parents, or guardians provided written consent for the use of patients’ images.

REFERENCES

1. Most SP. Anterior septal reconstruction: Outcomes after a modified extracorporeal septoplasty technique. *Arch Facial Plast Surg*. 2006;8:202–207.
2. Wilson MA, Mobley SR. Extracorporeal septoplasty: Complications and new techniques. *Arch Facial Plast Surg*. 2011;13:85–90.
3. Gubisch W. The extracorporeal septum plasty: A technique to correct difficult nasal deformities. *Plast Reconstr Surg*. 1995;7:218–226.
4. Rao JJ, Kumar EC, Babu KR, Chowdary VS, Singh J, Rangamani SV. Classification of nasal septal deviations: Relation to sinonasal pathology. *Indian J Otolaryngol Head Neck Surg*. 2005;57:199–201.
5. D'Andrea F, Brongo S, Rubino C. Extracorporeal septoplasty with paramarginal incision. *Scand J Plast Reconstr Surg Hand Surg*. 2001;35:293–296.
6. Stewart MG, Witsell DL, Smith TL, Weaver EM, Yueh B, Hannley MT. Development and validation of the Nasal Obstruction Symptom Evaluation (NOSE) scale. *Otolaryngol Head Neck Surg*. 2004;130:157–163.
7. Gubisch W. Twenty-five years experience with extracorporeal septoplasty. *Facial Plast Surg*. 2006;22:230–239.