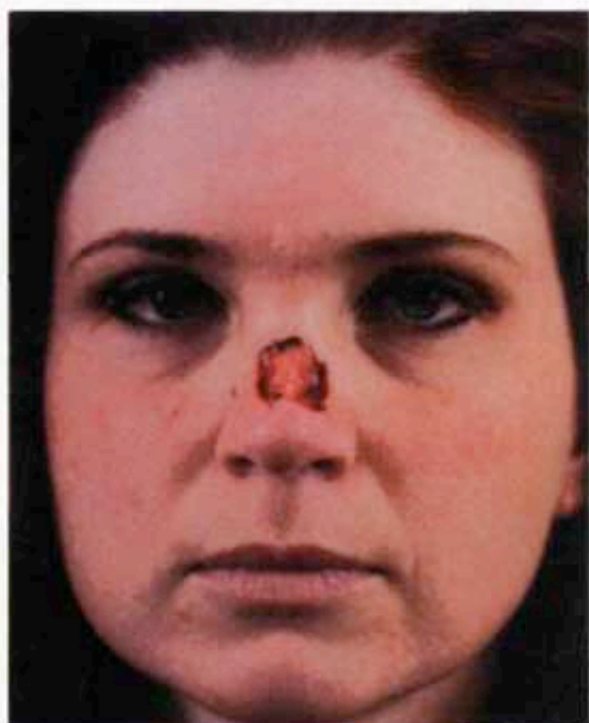

## Stretching the limits of full-thickness skin grafts

Steven Ross Mobley, MD



*Figure 1. Photograph shows the patient at the initial presentation.*

Modern nasal reconstruction of larger (>1.5 cm in diameter) defects frequently involves the use of interpolated flaps, such as the paramedian forehead flap (PMFF). This flap has rightly become the surgeon's workhorse for local repair of most medium- to large-sized nasal defects.

As part of obtaining informed consent, it is imperative that facial reconstructive surgeons educate patients on all the possible reconstructive options, including secondary intention healing and skin grafts. The author recommends that this education include showing before-and-after photographs of patients who have undergone various reconstructive modalities.

On occasion, some patients choose, for a variety of reasons, not to pursue a PMFF reconstruction. For these patients, the surgeon can offer the patient a full-thickness skin graft with the understanding that this will not be an obstacle to undergoing a PMFF at a later date, should the patient so desire.

A 35-year-old woman presented with an 18- × 20-mm cutaneous defect on the bridge and sidewalls of the nose (figure 1). For various reasons, she was very interested in pursuing reconstructive options other than PMFF, and she eventually opted for a full-thickness skin graft repair. The original defect was modified with local tissue transfers;

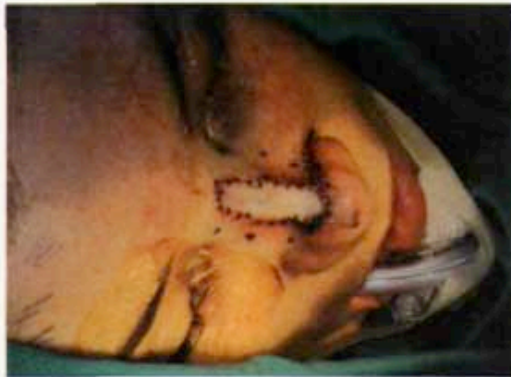

Figure 2. The defect is modified with local tissue transfers to fit within the nasal bridge aesthetic subunit.

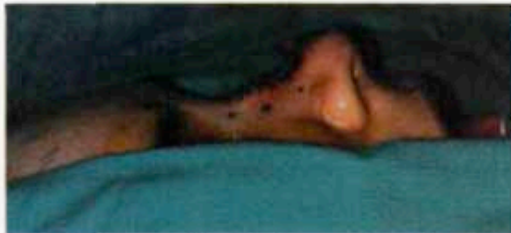

Figure 3. Intraoperatively, there is a poor three-dimensional contour match.

including a left cheek advancement flap, to create a defect that would lie within the boundaries of the nasal bridge aesthetic subunit (figure 2). Despite a poor contour match on the operating table (figure 3), the final result was aesthetically acceptable to both the patient and physician (figure 4). The appearance of the grafted skin was more glassy than that of the surrounding normal nasal skin. Still, the patient was content to overcome this by applying make-up.

Reconstructive surgeons must always remember to fully inform their patients as to the variety of reconstructive options that are available for any given defect. We must also strive to individualize our treatment plans based on the circumstances of each patient.

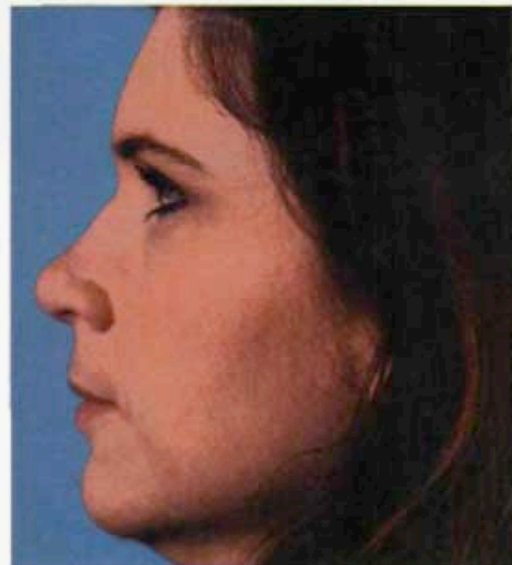
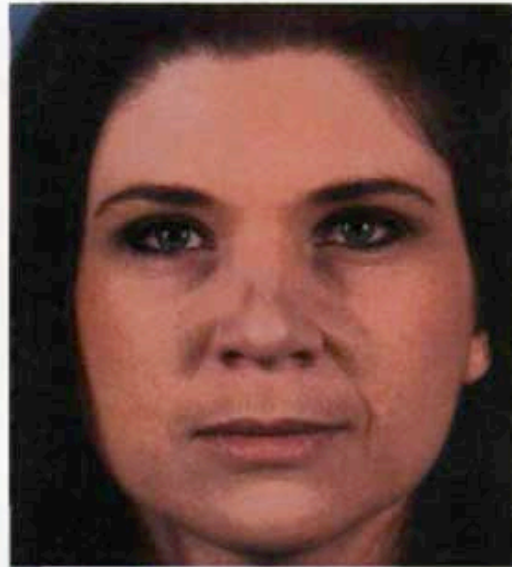

Figure 4. At 8 months postoperatively, the patient is satisfied with the cosmetic result.

**ENT**  
EAR, NOSE & THROAT  
JOURNAL

Visit our Web site and check out all the clinics published in  
*ENT Journal* for the past six years—in **COLOR**.

[www.entjournal.com](http://www.entjournal.com)