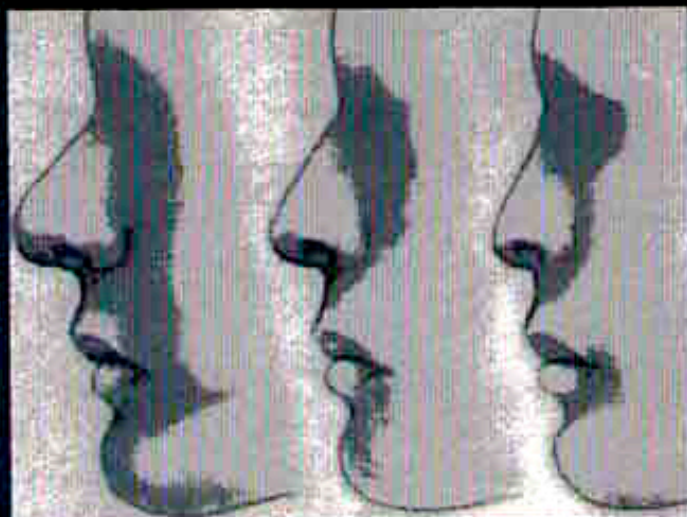


Blepharoplasty

# FACIAL PLASTIC SURGERY CLINICS OF NORTH AMERICA



November 2005

Volume 13

Number 4

theclinics.com

GUEST EDITOR

Paul S. Nassif, MD

Steven R. Mobley, MD



## Anatomy of the Eyelids

Sam P. Most, MD<sup>a</sup>, Steven Ross Mobley, MD<sup>b,\*</sup>,  
Wayne F. Larrabee, Jr, MD, MPH<sup>a</sup>

- Superficial topography of the lids
- Eyelid lamellae
- Orbicularis oculi
- Orbital septum
- Tarsal plates
- Neurovascular and lymphatic anatomy of the lids
- Postseptal orbital fat compartments
- Upper lid retractors
- Lower lid retractors
- Summary
- References

As the variety and complexity of periorbital surgical procedures increase, so must the facial plastic surgeon's understanding of related eyelid anatomy. This article has two general goals: (1) to reacquaint the reader with well-documented studies of eyelid anatomy, and (2) to review newer concepts of eyelid anatomy that are relevant to clinical practice.

### Superficial topography of the lids

The position and form of the eyebrow provide a structural foundation that has a profound impact on the appearance of the eye below. An exact analysis of eyebrow position is a critical first step in the preoperative evaluation of the eyelids. Ideal eyebrow aesthetics have been described differently for female patients versus male patients. Typically, female eyebrows are arched, with a peak whose horizontal high point is in line with, or slightly lateral to, the lateral limbus of the eye [Fig. 1]. At this highest point, the ideal brow should lay at least 1 cm above the superior orbital rim. By contrast, the male brow has been described as less peaked and lying more closely to the orbital rim.

Eyebrow position is the result of opposing forces. A ptosis of the eyebrow is a common symptom in patients seeking functional or aesthetic brow surgery. The frontalis muscle is the sole brow elevator. The orbicularis oculi, corrugators, and procerus muscles work in concert with the constant force of gravity to contribute to brow descent.

Eyebrow hair follicle direction needs to be well understood. This directionality of the brow cilia is an important consideration when designing incisions in the brow and brow hair transplant techniques. Beginning medially, the eyebrow hair follicles are all directed more superiorly. Centrally and laterally, the upper brow follicles are directed inferiorly, and the lower brow follicles are directed superiorly [1].

Fig. 1 depicts many important anatomic relationships. The lateral canthus is typically 2 to 4 mm superior to the medial canthus. The adult palpebral fissures average 10 to 12 mm vertically and 28 to 30 mm horizontally. The distance from the lateral canthus to the orbital rim is typically 5 mm. The upper eyelid is positioned at, or 1 to 2 mm below, the upper limbus [Fig. 1]. The highest point

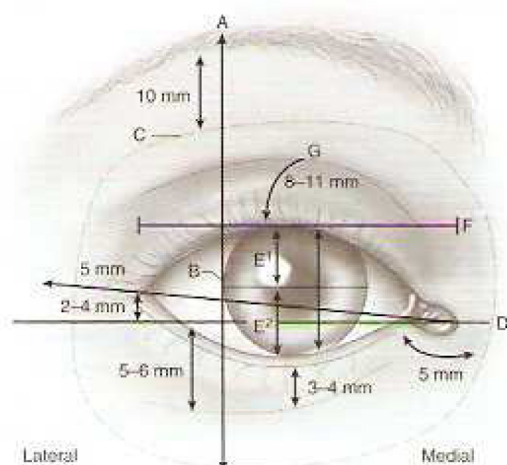
<sup>a</sup> Division of Facial Plastic and Reconstructive Surgery, Department of Otolaryngology–Head & Neck Surgery, University of Washington, Box 354716, 4245 Roosevelt Way NE, Seattle, WA 98105, USA

<sup>b</sup> Division of Otolaryngology, University of Utah Health Sciences Center, 50 North Medical Drive, SOM 3C-120, Salt Lake City, UT 84132, USA

\* Corresponding author. Division of Otolaryngology, University of Utah Health Sciences Center, 50 North Medical Drive, SOM 3C-120, Salt Lake City, UT 84132.

E-mail address: steven.mobley@hsc.utah.edu (S.R. Mobley).





**Fig. 1.** Topography of the eyelid. (A) The highest point of the brow is at, or lateral to, the lateral limbus. (B) The inferior edge of the brow is typically 10 mm superior to the supraorbital rim. (C) Also shown are ranges for average palpebral height (10–12 mm), width (28–30 mm), (D) and upper lid fold (8–11 mm, with gender and racial differences). Note that the lateral canthus is 2 to 4 mm higher than the medial canthus. (E) Intrapalpebral distance measures 10–12 mm. (E<sup>1</sup>) equals mean reflex distance 1. (E<sup>2</sup>) equals mean reflex distance 2. (F) Palpebral width. (G) Upper lid fold is 8–11 mm.

of the upper lid margin is just nasal to a vertical line drawn through the center of the pupil. It is important to note this contour in ptosis repair to ensure a natural-appearing upper lid margin. The position of the upper eyelid crease varies with ethnicity. In the occidental upper lid, the crease is typically 7 to

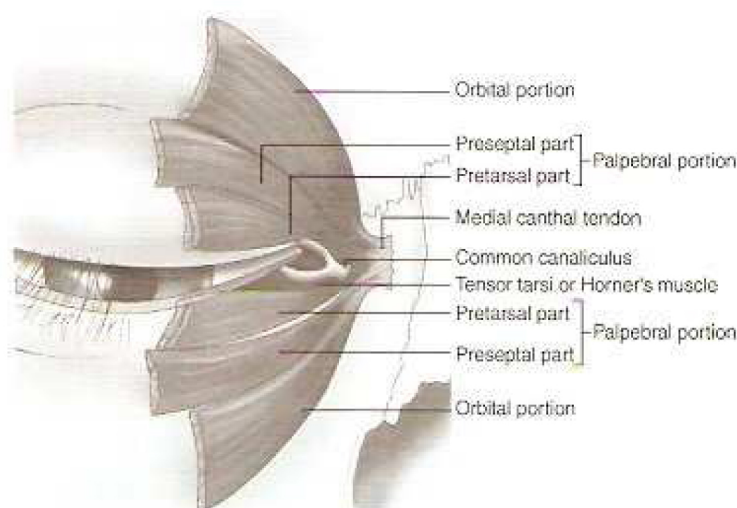
8 mm above the lid margin in men and 10 to 12 mm above the lid margin in women. In Asians, the upper lid crease may be lower or absent owing to lower insertion of the septum and variable or absent insertion of the levator aponeurosis into the upper lid skin [2,3].

The lower lid margin typically rests at the inferior limbus. The low point of the lower lid margin is just lateral to the pupil. The malar and nasojugal folds represent the cutaneous insertion of the orbimalar ligament, a distinct bony attachment of the orbicularis oculi [4].

Intrapalpebral distance is between 10 and 12 mm on average. This measurement can be divided into the mean reflex distance (MRD) 1 and 2. MRD1 represents the distance from the center of the pupil up to the inferior edge of the upper eyelid. MRD2 represents the distance from the center of the pupil down to the superior edge of the lower eyelid. For example, a patient with eyelid ptosis would have a decreased intrapalpebral distance but, more specifically, the MRD1 measurement would be decreased. In contrast, a patient with a lower lid ectropion would have an enlarged intrapalpebral distance, corresponding to the increase in the MRD2 measurement. Using the MRD1 and MRD2 terms properly facilitates clear communication between colleagues.

### Eyelid lamellae

The structures comprising the layers of the upper and lower eyelids are traditionally divided into anterior, middle, and posterior lamellae. In the lower eyelid, the anterior lamella is composed of



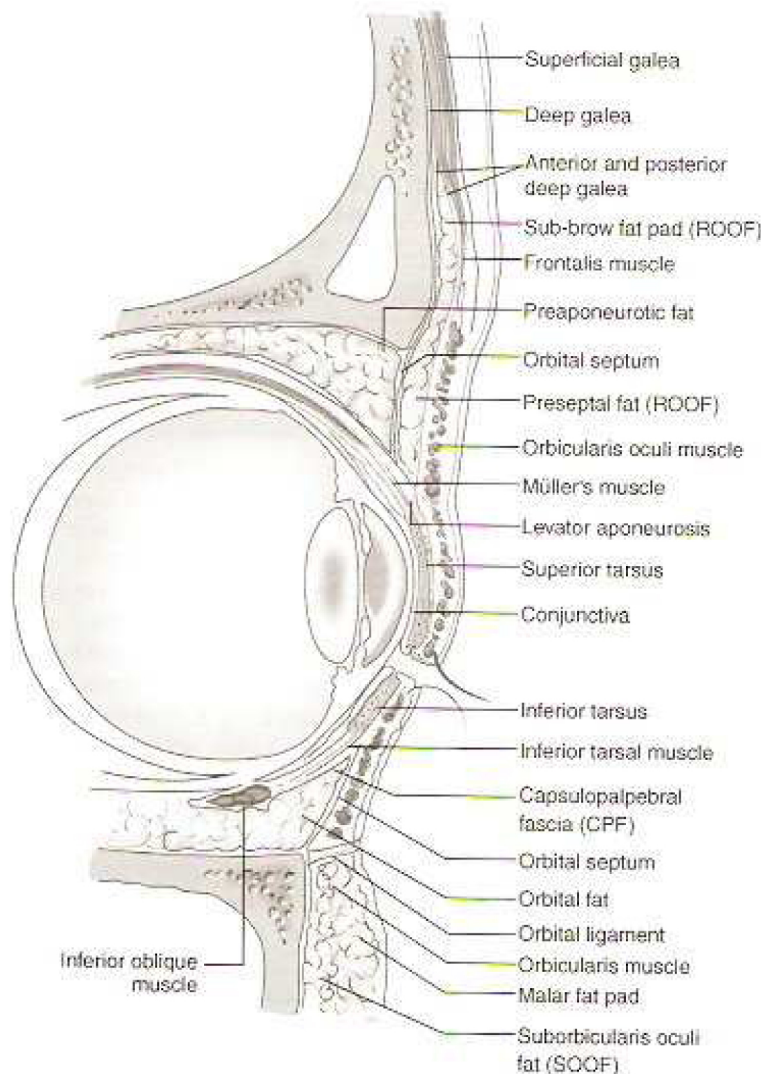
**Fig. 2.** Orbicularis oculi muscle. The muscle is traditionally divided into orbital and palpebral portions. The orbital portion arises from the anterior aspect of the MCT and the periosteum above and below it. The palpebral portion is further subdivided into pretarsal and preseptal portions, each lying over the tarsal plate or orbital septum, respectively.

the skin and underlying orbicularis muscle. The posterior lamella consists of the tarsus, septum, and underlying conjunctiva. The orbital septum separating the orbital contents from the preseptal structures is the middle lamella, although this nomenclature is not as consistently used as the former two.

### Orbicularis oculi

Eyelid skin is extremely thin and nearly devoid of subcutaneous fat. Deep to the skin lies the orbicularis muscle. This muscle is traditionally divided into orbital and palpebral portions. The orbital portion arises from the anterior aspect of the medial canthal tendon (MCT) and the periosteum

above and below this tendon. The palpebral portion is further subdivided into pretarsal and preseptal portions, lying over the tarsal plate and orbital septum, respectively [Fig. 2] [5,6]. The preseptal portion arises from two heads. The deep head arises from the posterior crest of the lacrimal fossa as well as the fossa itself. The superficial head arises from the MCT. The pretarsal portion also arises from two heads. The deep head (Horner's muscle) arises from the posterior lacrimal crest whereas the superficial head arises from the MCT. The superficial heads of the pretarsal and preseptal portions arise from the MCT whereas the deep heads arise posterior to some portion of the lacrimal system. The action of the medial palpebral portion of the orbicularis oculi is important for



**Fig. 3.** Cross-sectional anatomy of the upper and lower lids. The capsulopalpebral fascia and inferior tarsal muscle are retractors of the lower lid whereas Müller's muscle, the levator muscle, and its aponeurosis are retractors of the upper lid. Note the preseptal positioning of the retro-orbicularis oculi and suborbicularis oculi fat (ROOF and SOOF, respectively). The orbitomalar ligament arises from the arcus marginalis of the inferior orbital rim and inserts on skin of the lower lid, forming the nasojugal fold.

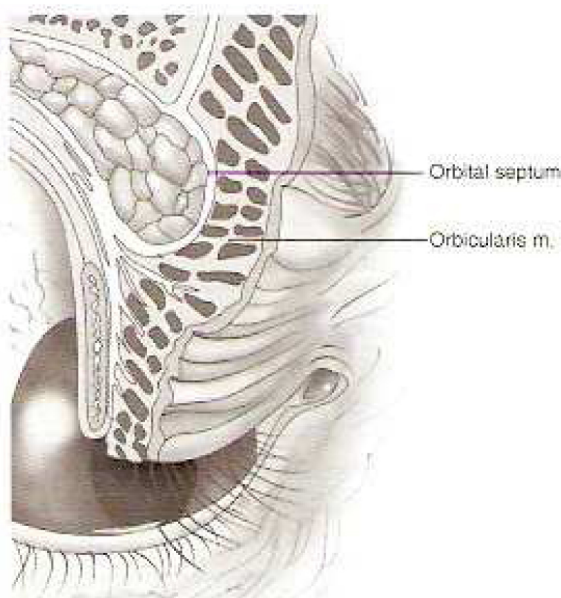


function of the lacrimal pump mechanism [5]. In particular, the contraction of Horner's muscle (which is occasionally defined to include the deep head of the preseptal muscle as well) draws the eyelids medially and posteriorly, aiding in excretory lacrimal function. Laterally, the pretarsal and preseptal muscles merge to form the lateral canthal tendon [5] (or lateral palpebral ligament).

The retro-orbicularis oculi fat pad (ROOF) is a submuscular fat pad that sits deep to the interdigitation of the frontalis and orbicularis oculi muscles [Fig. 3] [7,8]. The orbitomalar ligament arises from the arcus marginalis of the inferior orbital rim and inserts on skin of the lower lid, passing through the orbicularis [Fig. 3]. The malar and nasojugal folds represent the cutaneous insertion of this ligament [4]. Loosening of the septum above this ligament and concomitant descent of midfacial soft tissues inferior to this ligament results in the typical biconcave appearance of the midface with aging [9]. Analogous to the ROOF of the upper lid, a suborbicularis oculi fat pad (SOOF) lies deep to the orbicularis muscle in the lower lid [10]. Repositioning the SOOF is an important consideration in rejuvenation of the midface.

### Orbital septum

The orbital septum separates the orbital contents (postseptal) from external (preseptal) structures. The orbital septum originates from the arcus marginalis, a white fibrous line that arises circumferentially from the periosteum of the orbital rim. The



**Fig. 4.** The aging upper eyelid. Weakening of the orbital septum is thought to cause herniation of orbital fat in the upper and lower lids.

orbital septum lies deep to the orbicularis muscle. In the occidental upper lid, the septum typically fuses with the levator aponeurosis 2 to 3 mm above the tarsus, although this point can vary from 0 to 10 mm from the superior tarsal edge. The fusion is more inferior or absent in the Asian lid [2,3]. In the lower lid, the septum fuses with the capsulopalpebral fascia 5 mm inferior to the tarsus. Weakening of the septum with age results in prolapse of the postseptal fat anteriorly. Because the orbital septum is weakened and prolapsed but intact, the postseptal fat is described as pseudoherniated [Fig. 4].

### Tarsal plates

Although anatomically the tarsus resembles a cartilaginous structure, in actuality it is made up of dense fibrous tissue. The average upper tarsal plate measures 10 to 12 mm vertically, whereas the lower plate measures 4 mm. Medially, the tarsal plates are anchored to the orbital rim by the MCT. As described earlier, the MCT inserts on the anterior and posterior lacrimal crests. Laterally, the tarsal plates are anchored to the orbital rim at Whitnall's tubercle by the lateral canthal tendon [11].

### Neurovascular and lymphatic anatomy of the lids

The main arterial supply to the eyelids comes from distal branches of the internal and external carotid artery system. The terminal arterial branches of the internal carotid system include the lacrimal, supra-orbital, ophthalmic, frontal, and nasal arteries. Although the lower lid has a poorly developed arcade system, the upper lid has well-defined anastomoses between the nasal and lacrimal arteries in the form of a dual-arcade system. The marginal arcade of the upper eyelid is located 2 to 3 mm from the upper eyelid (lash line) margin. The peripheral arcade lies along the upper tarsal border. These arcades have a role in the vascular supply of pedicled tarsconjunctival flaps. The external carotid system contributes to the vasculature of the midface and lids via branches of the superficial temporal, infraorbital, and angular (terminal branch of the facial) arteries.

The lymphatics of the eyelids can be divided into a superficial (pretarsal) plexus and a deep (post-tarsal) plexus [12]. Although previously these plexus were thought to be freely interconnected, new evidence suggests they may be separate [12]. Damage to this network during surgery on the eyelid may result in chemosis postoperatively [13,14].



Two primary lymphatic drainage patterns are traditionally described: (1) primary lymph node drainage from the medial portion of the eyelids to the submandibular nodes and (2) lateral eyelid drainage to the preauricular lymph nodes. More recent lymphoscintigraphic studies in a primate model have demonstrated a more complicated pattern [15]. Specifically, the entire upper lid, medial canthus, and lateral lower lid drain to the parotid lymph nodes. The medial and central lower eyelid, as well as the central upper eyelid, drain to submandibular lymph nodes [15]. Notably, this pattern suggests a dual drainage from the central upper lid.

### Postseptal orbital fat compartments

The postseptal fat of the superior orbit is traditionally divided into two compartments: the central (or preaponeurotic) and the medial (or nasal) fat pads. These central and medial pockets are separated by the trochlea and some thin fascial strands from Whitnall's ligament. Whitnall's ligament extends laterally over the lacrimal gland to the superior edge of the lateral rectus muscle [16]. The medial fat pad is paler and firmer and is associated with the medial palpebral artery and infratrochlear nerve. Knowledge of the differences in the appearance of the central and medial fat pads is crucial for successful periorbital surgery. The preaponeurotic central fat is a key landmark in ptosis surgery, especially in revision surgery. The trochlea that separates these fat pockets must be protected during aesthetic blepharoplasty. Damage to the trochlea may result in superior oblique palsy or Brown's syndrome [17].

The inferior postseptal fat pads are divided into three compartments: the lateral, central, and medial. The central and lateral compartments are really continuous, separated anteriorly by Lockwood's ligament or the arcuate expansion of the inferior oblique muscle and an extension of the capsulopalpebral fascia. This structure courses inferotemporally. The inferior oblique muscle separates the medial and central fat compartments. As is true in the upper lid, the medial fat is paler and more fibrous than the fat located more laterally.

### Upper lid retractors

The levator palpebrae superioris is one of the retractors of the upper lid and is innervated by the third cranial nerve. The muscle portion arises from the greater wing of the sphenoid and is typically 40 mm long. The tendinous distal portion is 14 to

20 mm long and is termed the *levator aponeurosis* [see Fig. 3]. It is found deep to the preaponeurotic fat in the upper lid. The transition from the muscular to tendinous portion occurs in the region of Whitnall's ligament, a condensation of the superior sheath of the levator muscle. The central portion of the aponeurosis inserts on the anterior tarsal surface via an elastic fiber attachment [18]. The lateral horns of the aponeurosis separate the lacrimal and palpebral portions of the lacrimal gland before inserting onto the lateral canthal tendon. The medial horn of the aponeurosis inserts with the posterior portion of the MCT on the posterior lacrimal crest. With advancing age, the levator may disinsert, resulting in blepharoptosis [19].

In contrast to the striated muscle of the levator palpebrae superioris, the tarsal muscle of Müller is composed of smooth muscle fibers. This structure lies deep to the levator and is firmly adherent to the underlying conjunctival mucosa. It is innervated by the sympathetic system and inserts on the superior tarsal border. Contraction of this muscle contributes about 2 mm to lid retraction.

### Lower lid retractors

The lower eyelid retractors provide dynamic movement to the lower eyelid analogous to the retractors of the upper lid. Disorders (acquired or developmental) of this system can cause eyelid malposition, including both ectropion and entropion. The primary retractors of the lower lid are the capsulopalpebral fascia and the inferior tarsal muscle [20]. The capsulopalpebral fascia of the lower lid is analogous to the levator aponeurosis of the upper lid [Fig. 3]. It arises from the inferior rectus muscle, splits to extend around the inferior oblique muscle, and forms Lockwood's ligament. Ultimately, it inserts on the inferior border of the tarsus. This fascia transmits the force of the inferior rectus muscle and exerts its action on the lower lid. The inferior tarsal muscle is analogous to Müller's muscle. Like its counterpart, it lies deep to the primary retractor, the capsulopalpebral fascia. Furthermore, it is composed of smooth muscle and is innervated by the sympathetic system. Incision of the lower lid retractors during transconjunctival blepharoplasty rarely results in eyelid malposition.

### Summary

An intimate knowledge of the topographic and functional anatomy of the eyelids, as well as the interrelationship between the two, is essential to the surgeon performing aesthetic and reconstructive surgery in the periorbital area.



## References

- [1] Lemke BN, Stasior GO. Eyebrow incision making. *Adv Ophthalmic Plastic Reconstr* 1983;2:19-23.
- [2] Chen WP. Asian blepharoplasty: update on anatomy and techniques. *Ophthalm Plast Reconstr Surg* 1987;3(3):135-40.
- [3] Chen WP. Asian blepharoplasty. In: Chen WP, editor. *Oculoplastic surgery: the essentials*. New York: Thieme; 2001. p. 211-24.
- [4] Kikkawa DO, Lemke BN, Dortzbach RK. Relations of the superficial musculoaponeurotic system to the orbit and characterization of the orbitomalar ligament. *Ophthalm Plast Reconstr Surg* 1996;12(2):77-88.
- [5] Jones LT. An anatomical approach to problems of the eyelids and lacrimal apparatus. *Arch Ophthalmol* 1961;66:111-24.
- [6] Jones LT. Anatomy of the tear system. *Int Ophthalmol Clin* 1973;13(1):3-22.
- [7] Lemke BN, Stasior OG. The anatomy of eyebrow ptosis. *Arch Ophthalmol* 1982;100(6):981-6.
- [8] Putterman AM, Urist MJ. Surgical anatomy of the orbital septum. *Ann Ophthalmol* 1974;6(3):290-4.
- [9] Hamra ST. Arcus marginalis release and orbital fat preservation in midface rejuvenation. *Plast Reconstr Surg* 1995;96(2):354-62.
- [10] May Jr JW, Fearon J, Zingarelli P. Retro-orbicularis oculi fat (ROOF) resection in aesthetic blepharoplasty: a 6-year study in 63 patients. *Plast Reconstr Surg* 1990;86(4):682-9.
- [11] Whitnall SE. On a tubercle on the malar bone, and on the lateral attachments of the tarsal plates. *J Anat Physiol* 1911;45:426-32.
- [12] Cook Jr BE, Lucarelli MJ, Lemke BN, et al. Eyelid lymphatics I: histochemical comparisons between the monkey and human. *Ophthalm Plast Reconstr Surg* 2002;18(1):18-23.
- [13] Kalin NS, Orlin SE, Wulc AE, et al. Chronic localized conjunctival chemosis. *Cornea* 1996;15(3):295-300.
- [14] Levine MR, Davies R, Ross J. Chemosis following blepharoplasty: an unusual complication. *Ophthalmic Surg* 1994;25(9):593-6.
- [15] Cook Jr BE, Lucarelli MJ, Lemke BN, et al. Eyelid lymphatics II: a search for drainage patterns in the monkey and correlations with human lymphatics. *Ophthalm Plast Reconstr Surg* 2002;18(2):99-106.
- [16] Sires BS, Lemke BN, Dortzbach RK, et al. Characterization of human orbital fat and connective tissue. *Ophthalm Plast Reconstr Surg* 1998;14(6):403-14.
- [17] Neely KA, Ernest JT, Mottier M. Combined superior oblique paresis and Brown's syndrome after blepharoplasty. *Am J Ophthalmol* 1990;109(3):347-9.
- [18] Stasior GO, Lemke BN, Wallow IH, et al. Levator aponeurosis elastic fiber network. *Ophthalm Plast Reconstr Surg* 1993;9(1):1-10.
- [19] Karesch JW. Diagnosis and management of acquired blepharoptosis and dermatochalasis. *Facial Plast Surg* 1994;10(2):185-201.
- [20] Hawes MJ, Dortzbach RK. The microscopic anatomy of the lower eyelid retractors. *Arch Ophthalmol* 1982;100(8):1313-8.